

# Comprehensive Treatment Plan

(Original case submitted by Dr. Nicholas DuVall)

## BIOGRAPHICAL INFORMATION:

### Patient Introduction/Data:


The patient is a 50 year-old African-American female who recently moved to San Antonio, TX from South Carolina. The patient is currently employed in the health care field. The patient states she recently had a dental evaluation but declined treatment due to finances. The patient reports a past dental history of primarily episodic/symptomatic dental treatment consisting of extractions to alleviate the pain.

### Medical History:

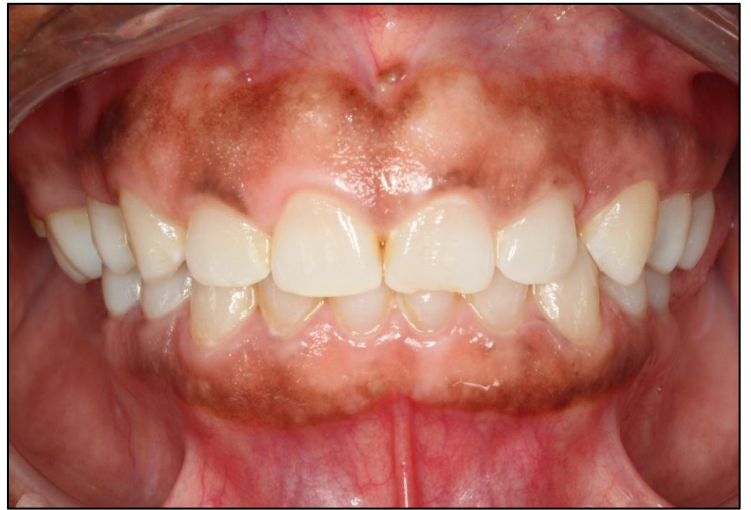COMPLETE IN INK DENTAL PATIENT MEDICAL HISTORY (This Form is Subject to the Privacy Act of 1974 - Use Number 642 - (20) Form 200)			
NAME (Last, First, Middle Initial) <i>Harrison, Gracie L.</i>	SPONSOR'S SSN [Redacted]	BIRTHDATE [Redacted]	ACTIVE DUTY ONLY (Circle Correct Responses - Are You Currently On)
ORGANIZATION (Active Duty) or Home Address [Redacted]	PATIENT'S SSN [Redacted]	AGE <i>50</i>	FLYING STATUS? YES NO
EMAIL ADDRESS (Military Address) [Redacted]	BUSINESS PHONE [Redacted]	HOME PHONE [Redacted]	SDP (PRP, SCL or PS)? YES NO
The Answers To The Following Questions Will Assist The Dentist In Evaluating Your General Health Prior To Providing Your Dental Treatment PLEASE READ CAREFULLY AND ANSWER EACH QUESTION AS ACCURATELY AS POSSIBLE			
1. WHAT IS YOUR IMPRESSION OF YOUR PRESENT OVERALL HEALTH? <i>Good</i>		2. YEAR OF LAST MEDICAL PHYSICAL? <i>2009</i>	
3. PLEASE DRAW A CIRCLE AROUND ANY OF THE FOLLOWING WHICH YOU HAVE HAD OR HAVE AT PRESENT:			
Heart Disease or Condition Angina Pectoris Enlarged Chest Pains <u>High Blood Pressure</u> Shortness of Breath Swollen Ankles Artificial Heart Valve Congenital Heart Disease Heart Murmur	Rheumatic Fever <u>Stroke</u> <i>STI</i> Hemochromatosis Bruise Easily Prolonged or Unusual Bleeding Anemia Blood Transfusion Sickle Cell Disease Arthritis	Asthma Hay Fever Emphysema Tuberculosis (TB) Diabetes Ulcers Kidney Trouble Liver Disease Jaundice (Other than birth)	Hepatitis Thyroid Disease Glaucoma Epilepsy or Seizures Fainting or Dizzy Spells AIDS or AIDS Related Complex HIV Positive Cold Sores Genital Herpes
Venereal Disease (Syphilis, Gonorrhea) Drug Addiction Psychiatric Treatment Cancer Radiation Therapy Chemotherapy Implant Prosthesis Unexplained Weight Loss			
CIRCLE YES OR NO FOR THE FOLLOWING QUESTIONS (If in Doubt, CIRCLE YES / IF YES, Please Give Details) CONTINUE COMMENTS ON BACK IF NECESSARY			
4. ARE YOU PRESENTLY, OR HAVE YOU BEEN UNDER THE CARE OF A PHYSICIAN IN THE PAST YEAR?			Yes <input checked="" type="radio"/> No <input type="radio"/>
5. ARE YOU PRESENTLY TAKING ANY MEDICINE OR DRUGS (OVER-THE-COUNTER / PRESCRIPTION / HERBAL SUPPLEMENTS)?			Yes <input checked="" type="radio"/> No <input type="radio"/>
6. ARE YOU ALLERGIC TO ANY MEDICINE OR MATERIALS (INCLUDING LATEX)?			Yes <input checked="" type="radio"/> No <input type="radio"/>
7. HAVE YOU EVER HAD A REACTION TO LOCAL ANESTHETIC?			Yes <input type="radio"/> No <input checked="" type="radio"/>
8. HAVE YOU EVER EXPERIENCED ANY COMPLICATION OR ILLNESS FOLLOWING DENTAL TREATMENT?			Yes <input type="radio"/> No <input checked="" type="radio"/>
9. DO YOU HAVE ANY DISEASES OR CONDITIONS NOT MENTIONED ABOVE?			Yes <input type="radio"/> No <input checked="" type="radio"/>
10. HAVE YOU EVER BEEN TOLD YOU WERE NOT ELIGIBLE TO BE A BLOOD DONOR?			Yes <input type="radio"/> No <input checked="" type="radio"/>
11. HAVE YOU EVER BEEN TOLD TO TAKE ANTIBIOTICS PRIOR TO DENTAL CARE?			Yes <input type="radio"/> No <input checked="" type="radio"/>
12. DO YOU USE TOBACCO? (If Yes, Please Circle Type And Give Frequency) SMOKE: CIGARETTES CIGAR PIPE SMOKELESS: CHEWING TOBACCO SNUFF or DIP			Yes <input type="radio"/> No <input checked="" type="radio"/>
13. WOMEN - ARE YOU PREGNANT? (If Yes, Please Circle Trimester) 1 2 3			Yes <input type="radio"/> No <input checked="" type="radio"/>
Check Box If Comments Added To Back Of Form	SIGNATURE OF PATIENT OR Legal Guardian (If Patient is a Minor) <i>Gracie L. Harrison</i>		DATE <i>7/26/2010</i>
DENTIST COMMENTS <i>#3 near to 2 weeks No stroke 1999 - 2 years ago #4 TX for HIV #5 previous, Avandia (200mg/12.5mg), Tylenol / Ibuprofen (pain), Act 81mg, Albuterol (100mcg/100mcg) - 1st dose #5 previous, Avandia (200mg/12.5mg), Tylenol / Ibuprofen (pain), Act 81mg, Albuterol (100mcg/100mcg) - 1st dose</i>			
COMMENTS ON BACK: Yes / No <i>27 Aug 10</i>			
BLOOD PRESSURE	DATE	BLOOD PRESSURE	DATE
<i>140/90</i>	<i>20 3-10</i>	<i>125/65</i>	<i>27 Aug 10</i>
DENTIST SIGNATURE	DATE	REVIEWER/DATE	REVIEWER/DATE
<i>Nicholas DuVall</i>	<i>26 Aug 10</i>	<i>Dr. DuVall</i>	<i>27 Aug 10</i>

## PHOTOGRAPHS:

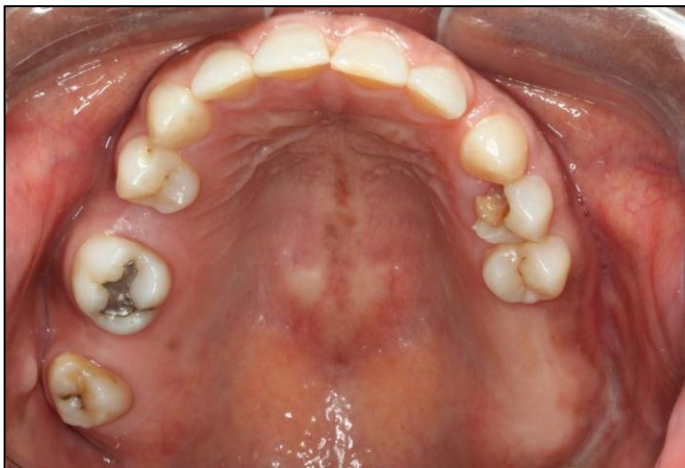### Pre-treatment Clinical Photographs:



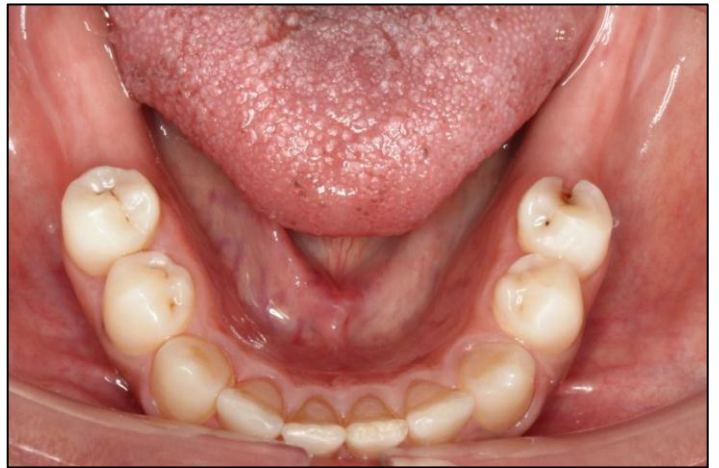*Full Face Frontal View*



*Anterior View in MIP*

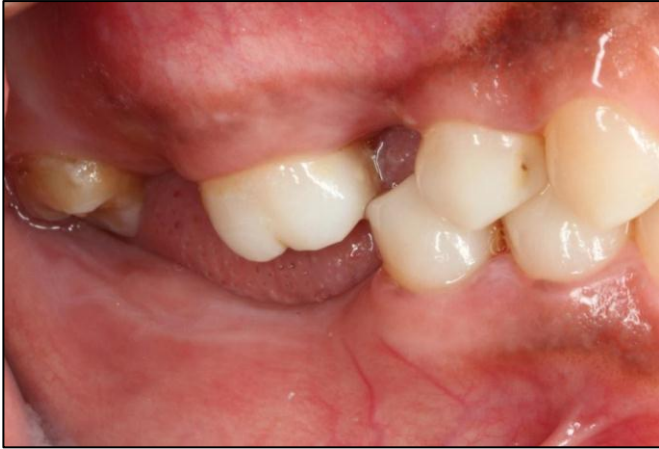

*Max Occlusal View*

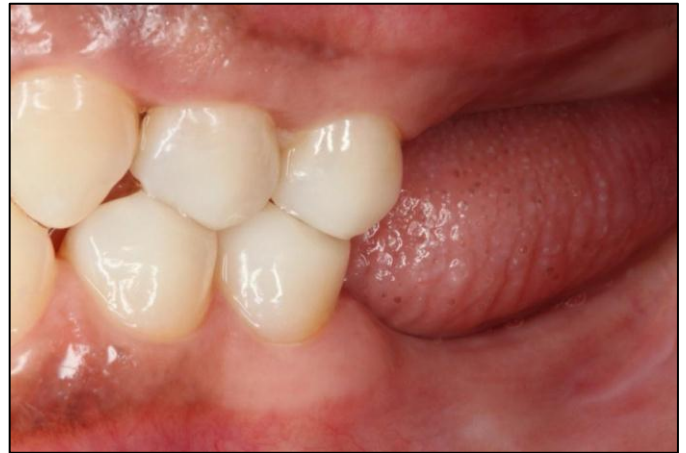

*Man Occlusal View*

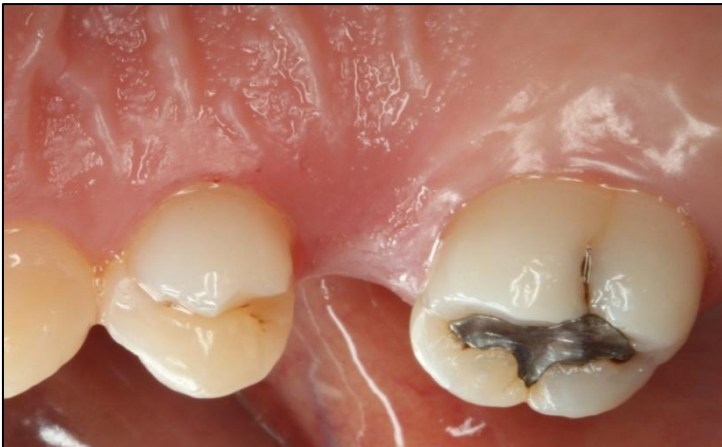



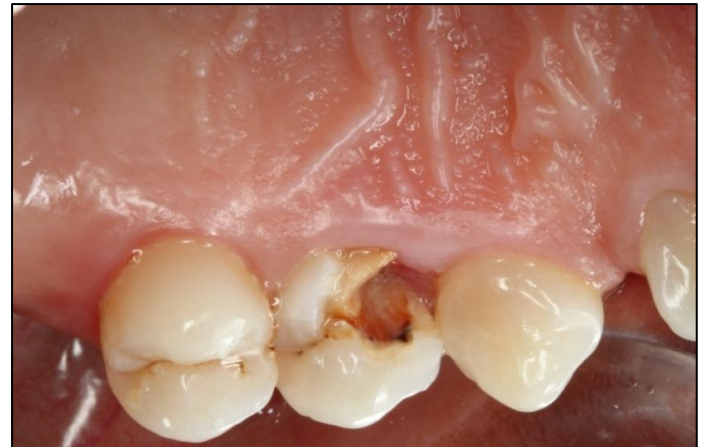*Right Buccal View in MIP*



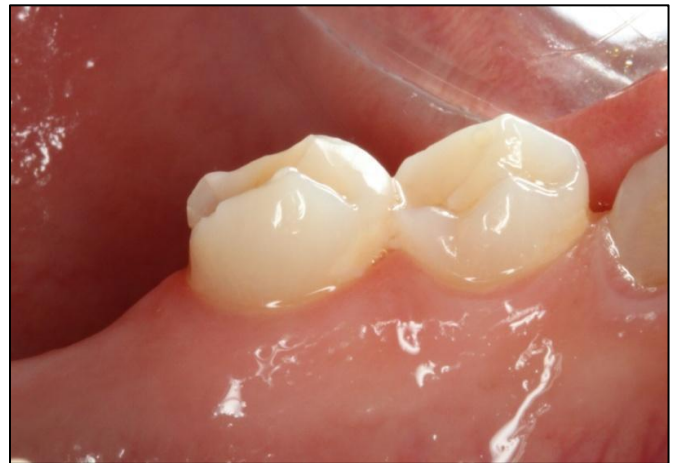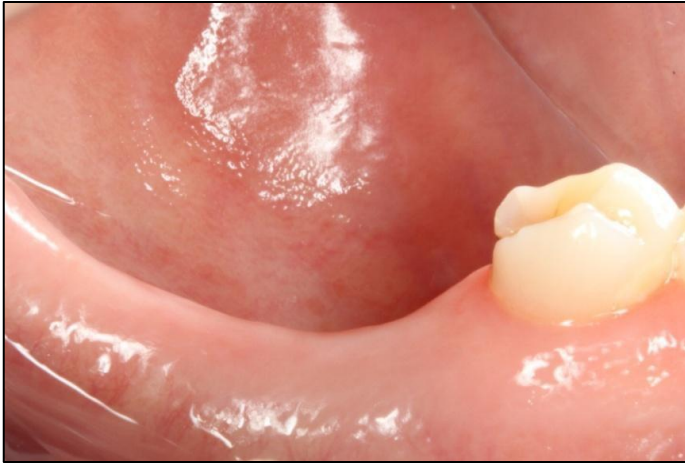
*Left Buccal View in MIP*



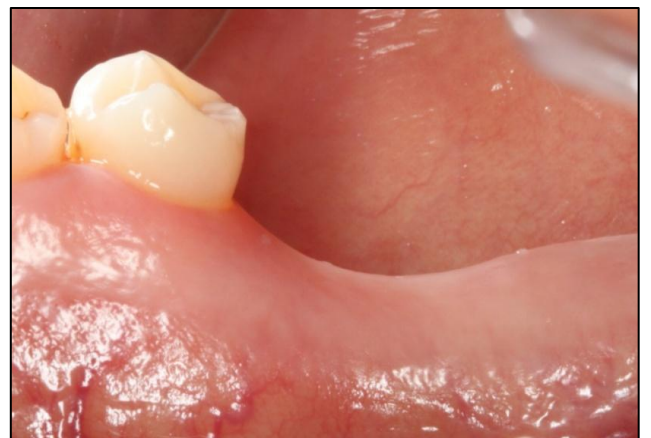
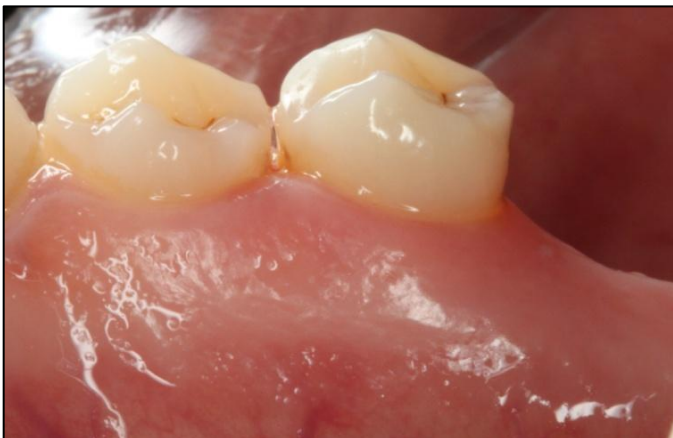*Max Right Lingual View*



*Max Left Lingual View*



*Man Left Lingual View*



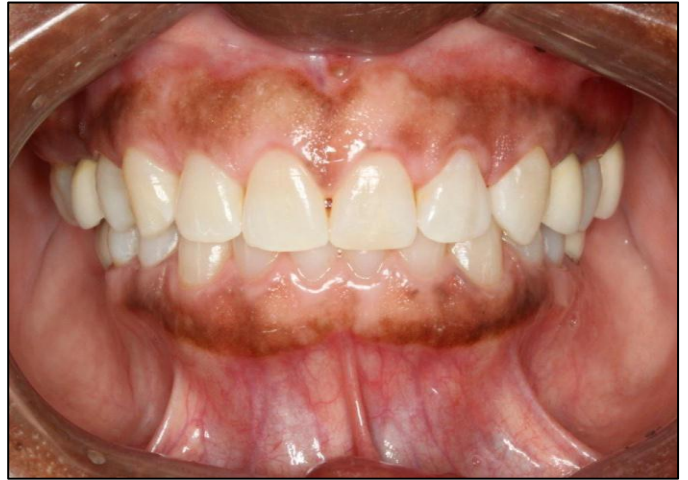*Man Right Lingual View*



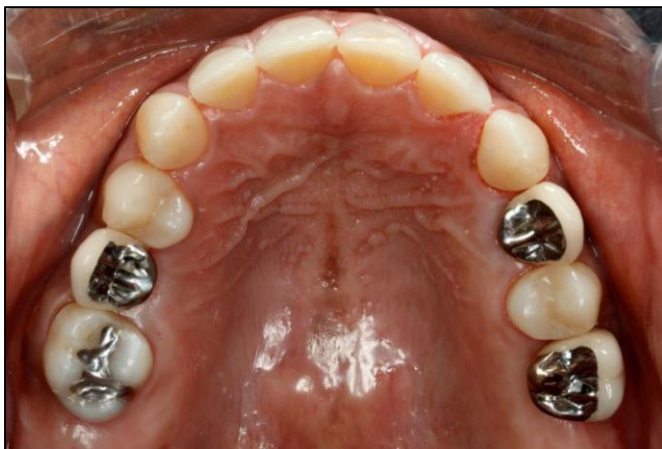
**Post-treatment Clinical Photographs:**



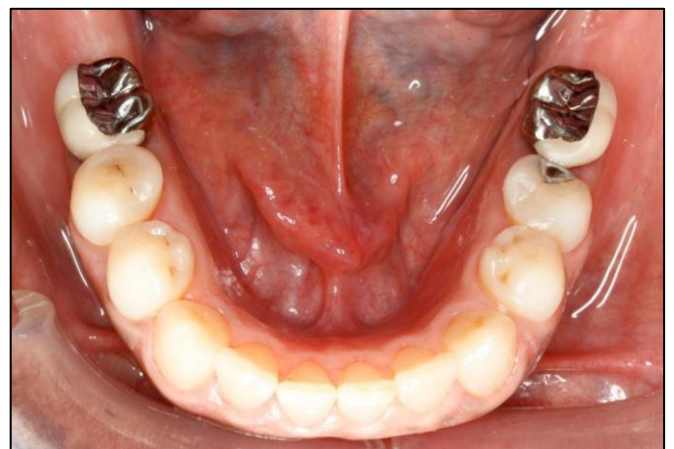*Full Face Frontal View*



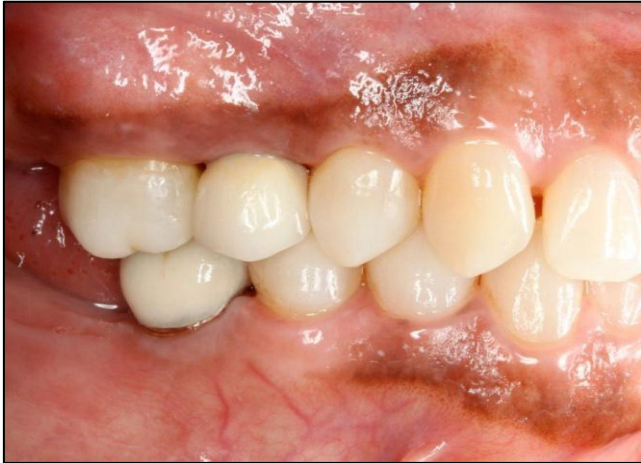*Anterior View in CO*



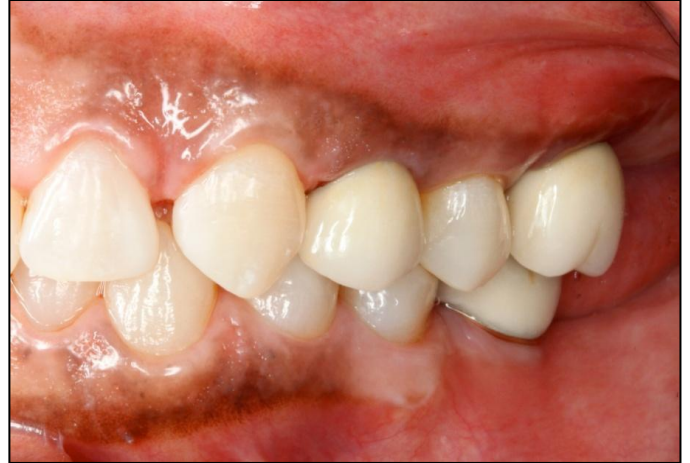*Max Occlusal View*



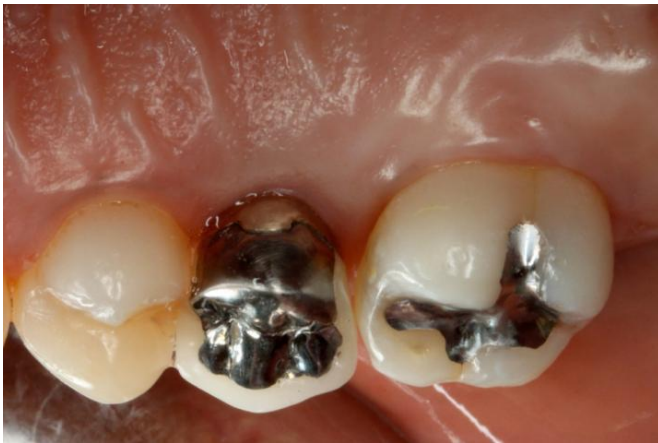*Man Occlusal View*



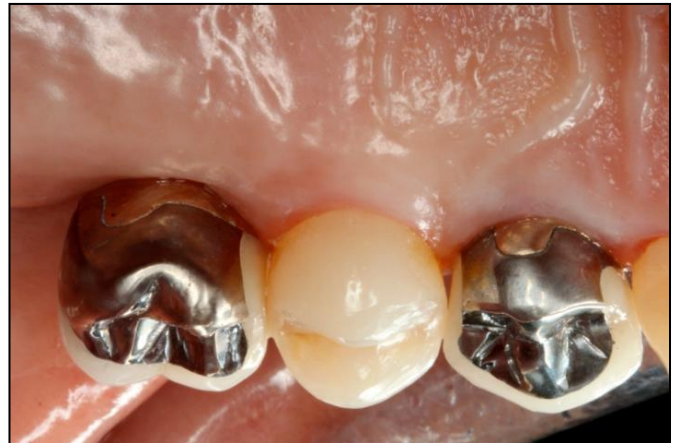*Right Buccal View in CO*



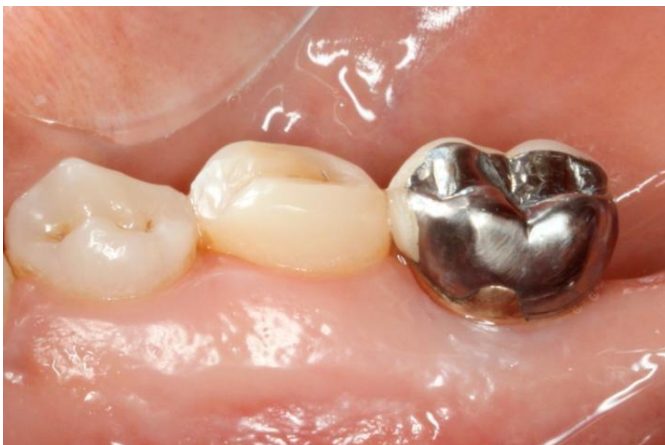*Left Buccal View in CO*



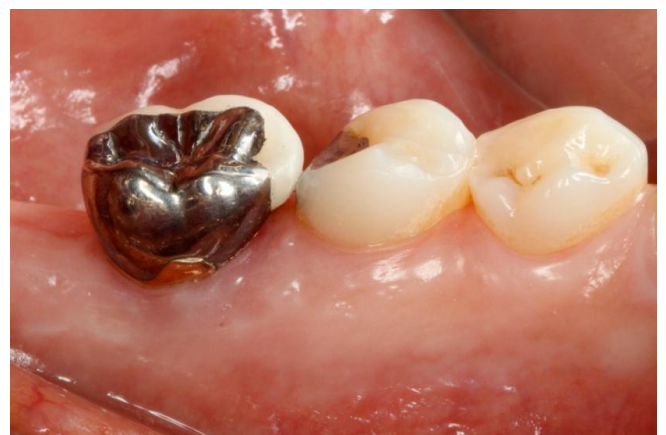*Max Right Lingual View*



*Max Left Lingual View*



*Man Right Lingual View*



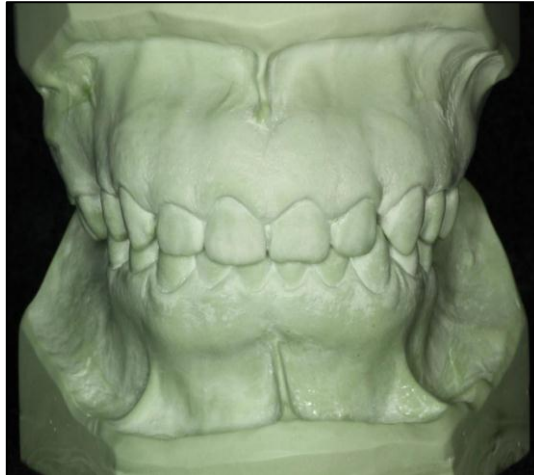*Man Left Lingual View*



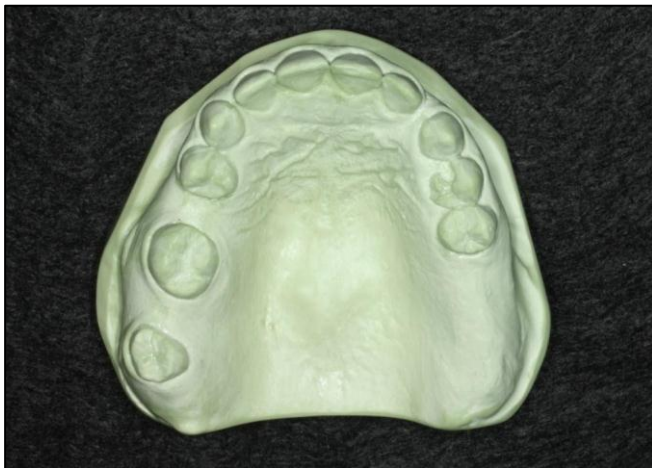**CASTS:**

**Pretreatment:**

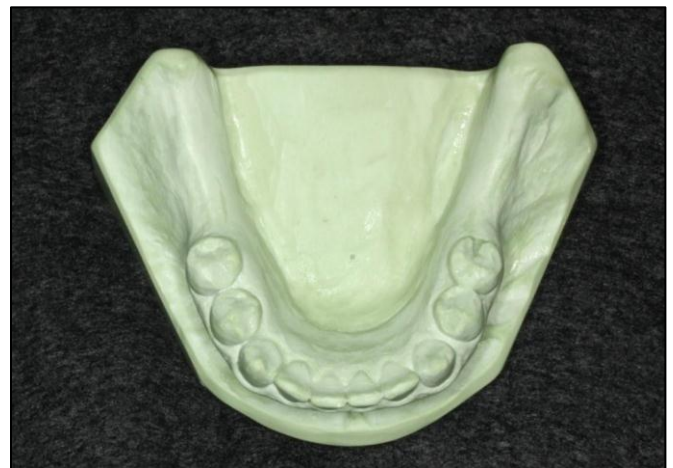---



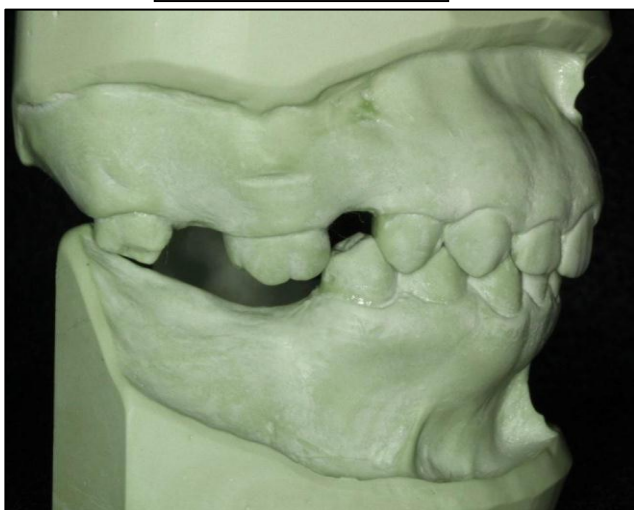*Anterior View in MIP*



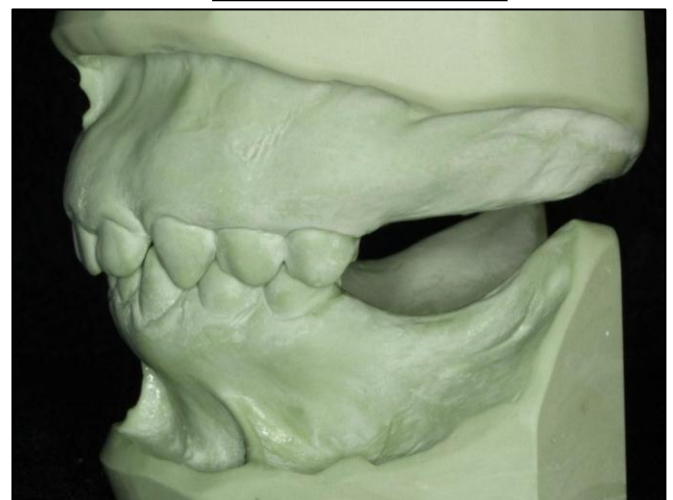*Max Occlusal View*



*Man Occlusal View*



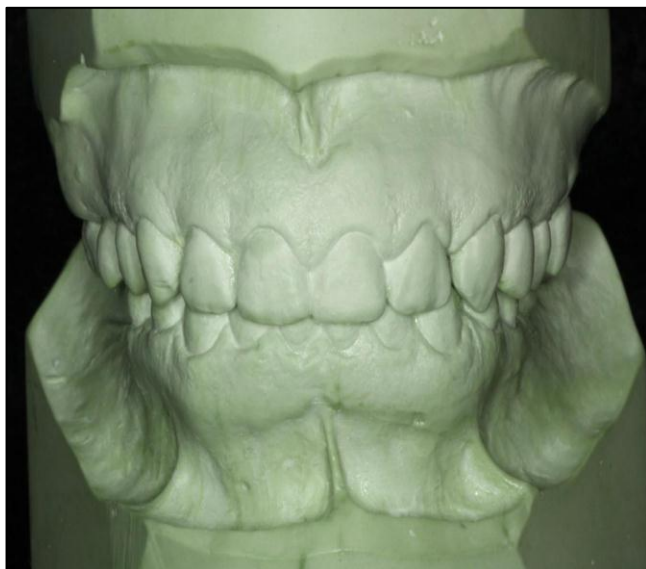*Right Buccal View in MIP*



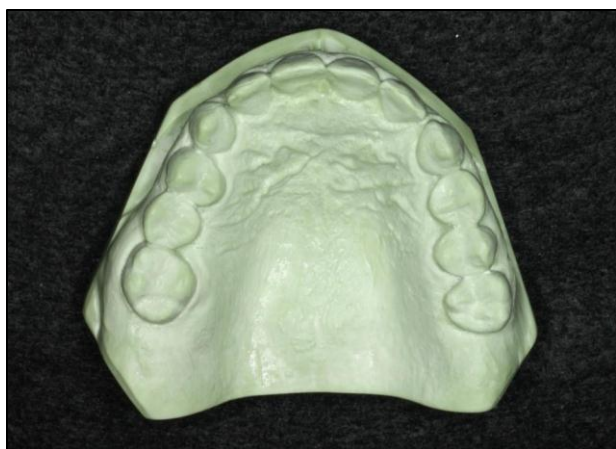*Left Buccal View in MIP*

**Post-treatment:**

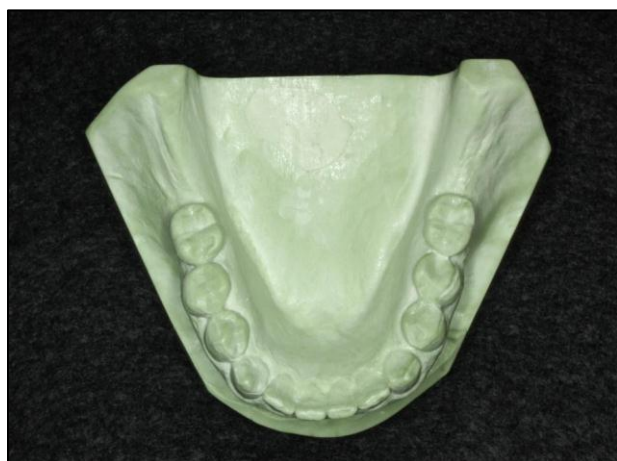---



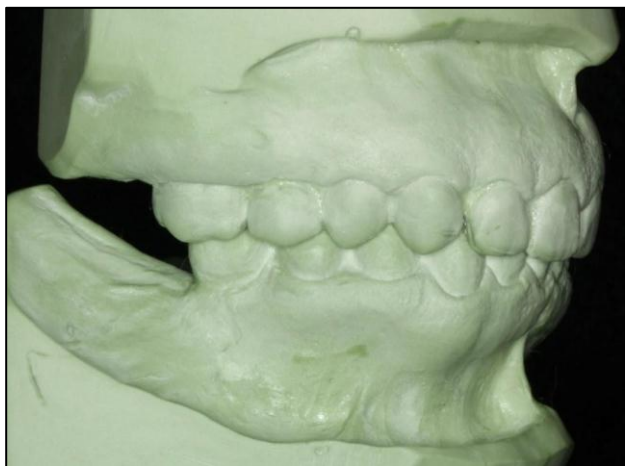*Anterior View in MIP*



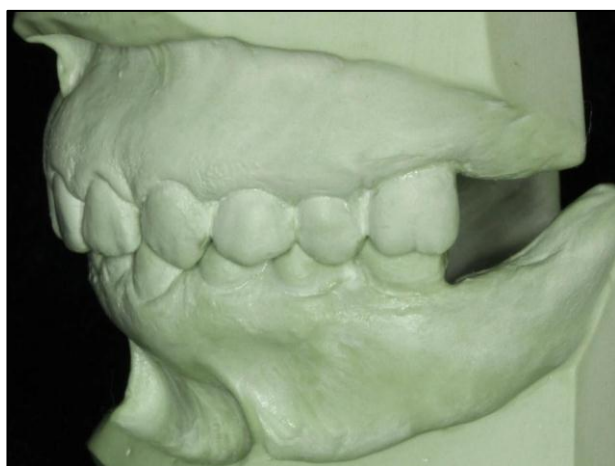*Max Occlusal View*



*Man Occlusal View*



*Right Buccal View in MIP*

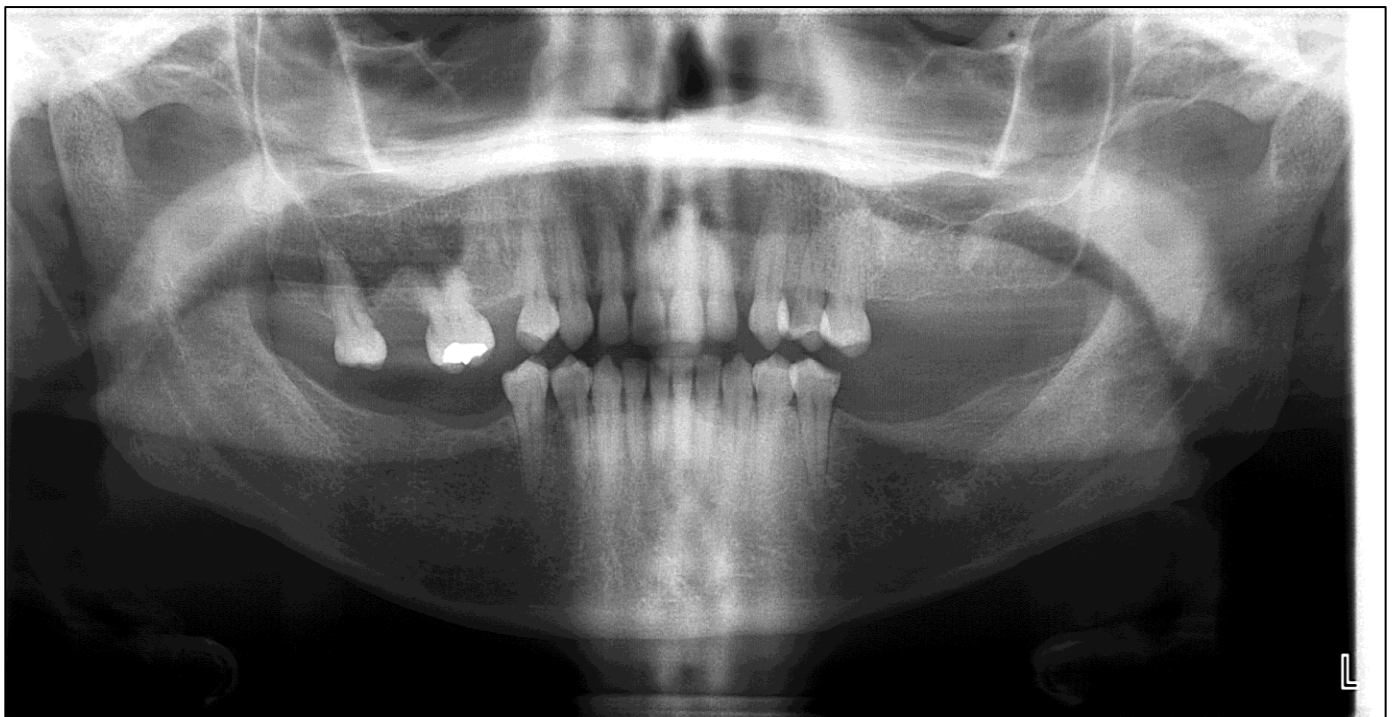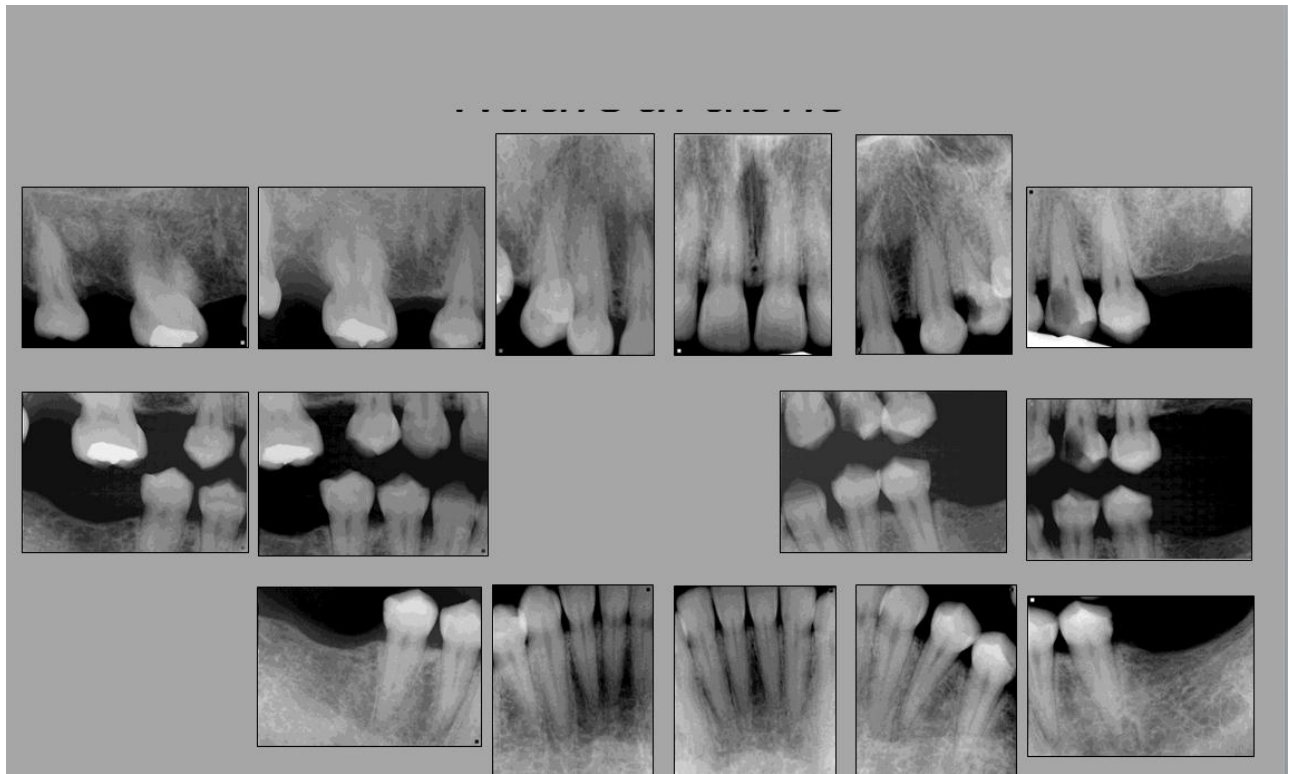


*Left Buccal View in MIP*

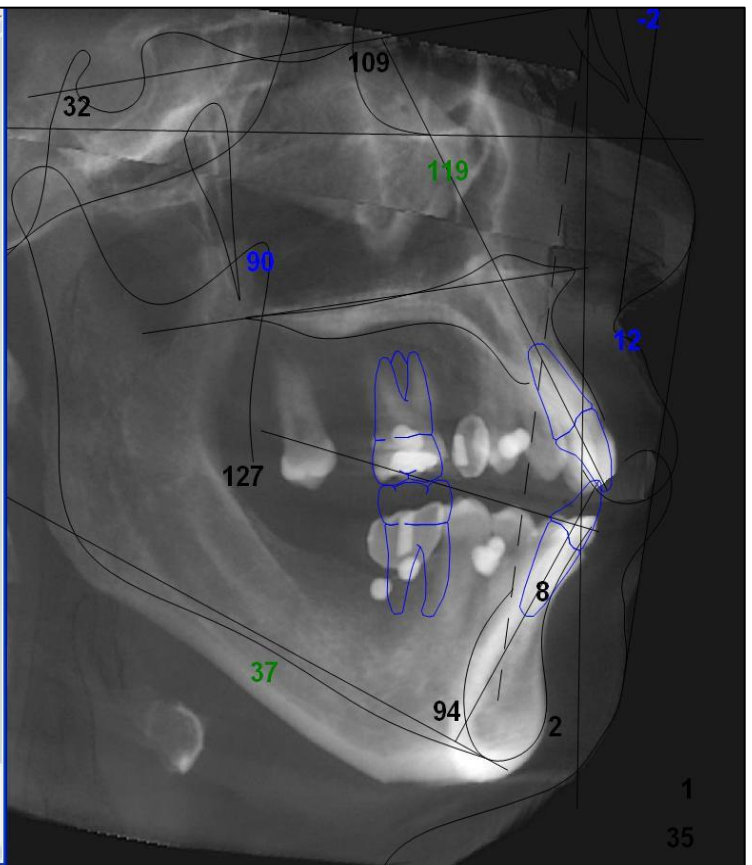


## RADIOGRAPHS:

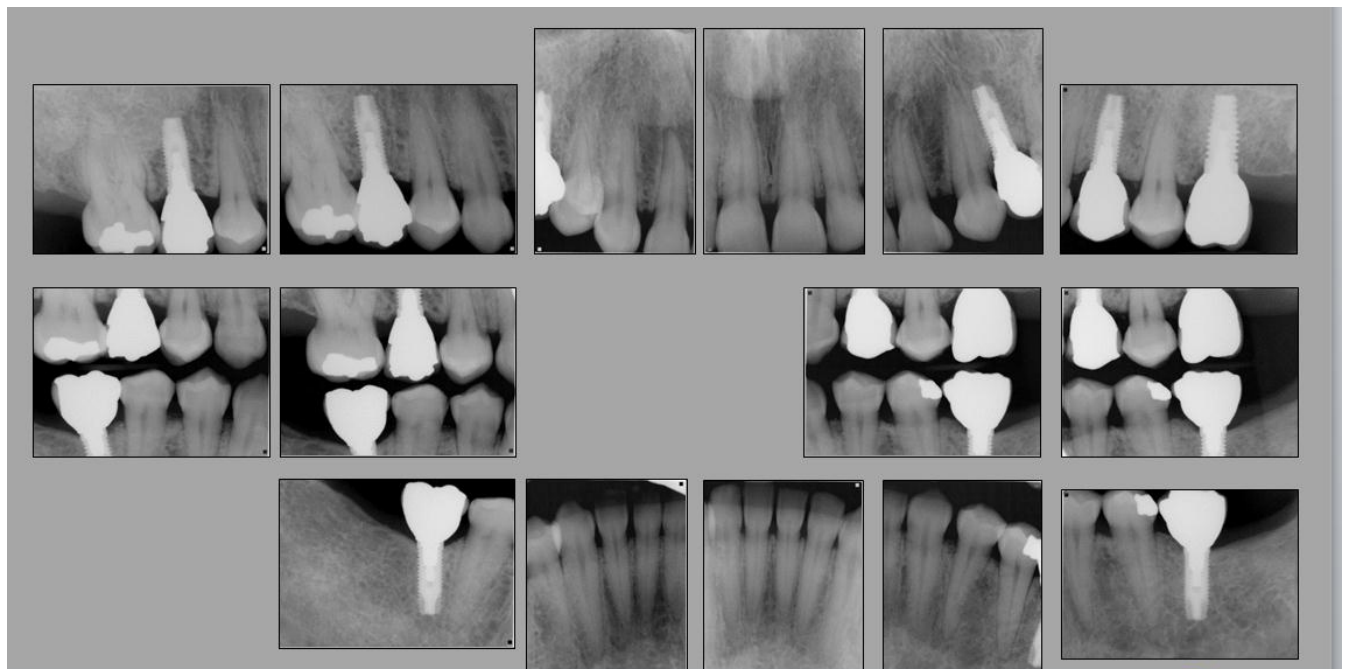
### Pretreatment:



Group/Measurement	Value	Norm	Std Dev	Dev Norm
<b>Skeletal AP</b>				
SNA (°)	74.3	81.4	4.4	-1.6 *
SNB (°)	76.6	78.2	3.9	-0.4
ANB (°)	-2.3	3.2	2.3	-2.4 **
A to N Vert (True Vert) (mm)	1.0	0.0	3.7	0.3
B to N Vert (True Vert) (mm)	5.8	-5.3	6.7	1.7 *
Pg to N Vert (True Vert) (mm)	8.1	-4.3	8.5	1.5 *
A-N Perpendicular (mm)	-5.2	1.1	2.7	-2.3 **
B-N Perpendicular (mm)	-6.2	-5.3	6.7	-0.1
Pog-N Perpendicular (mm)	-5.3	-0.3	3.8	-1.3 *
Mx Unit Length (Co-ANS) (mm)	90.3	100.9	3.9	-2.7 **
Mand Unit length (Co-Gn) (mm)	127.0	131.0	4.6	-0.9
Mx/Md Diff (Co-Gn - Co-ANS) (mm)	36.6	30.0	3.9	1.7 *
<b>Dental AP</b>				
UI - SN (°)	109.3	105.2	6.4	0.6
UI - NA (°)	35.0	23.8	6.1	1.8 *
UI - MA (mm)	12.0	5.5	2.7	2.4 **
UI - FH (°)	119.0	108.1	7.5	1.5 *
IMPA (LI-MP) (°)	93.6	95.3	6.6	-0.3
LI - NB (°)	26.0	26.4	7.3	-0.1
LI - MB (mm)	7.5	6.1	2.9	0.5
LI Protrusion (LI-APo) (mm)	8.1	2.8	2.9	1.8 *
LI to A-Po (°)	29.6	25.2	4.9	0.9
Wits Appraisal (mm)	0.6	-1.2	1.9	0.9
Interincisal Angle (UI-LI) (°)	121.3	126.6	10.0	-0.5
Overjet (mm)	1.4	2.0	1.0	-0.6
Pog - MB (mm)	1.7	2.4	2.5	-0.3
Holdaway Ratio (LI-MB:Pog-MB) (%)	4.6	1.0	100.0	0.0
FMIA (LI-FH) (°)	60.3	55.6	8.2	0.6
<b>Skeletal Vert</b>				
Total Anterior Face Ht (N-Me) (mm)	117.5	136.8	7.9	-2.4 **
Upper Face Height (N-ANS) (mm)	41.1	59.7	3.9	-4.8 ****
Lower Face Height (ANS-Me) (mm)	76.7	79.5	6.2	-0.5
Nasal Height (%)	35.0	43.0	100.0	-0.1
Post Facial Ht (Co-Gn) (mm)	56.8	66.1	4.1	-2.3 **
PFH:APH (%)	48.3	60.0	100.0	-0.1
FMA (MP-FH) (°)	26.1	28.7	5.2	-0.5
SN - GoGn (°)	32.2	32.6	5.2	-0.1
Occ Plane to SN (°)	10.3	31.3	3.1	-6.8 *****
Occ Plane to FH (°)	0.6	11.5	2.6	-4.2 *****
FH - SN (°)	9.7	3.1	3.6	1.8 *
<b>Dental Vert</b>				
UI - PP (UADH) (mm)	34.4	33.0	3.2	0.4
LI - MP (LADH) (mm)	46.6	48.9	3.0	-0.8
UG - PP (UPDH) (mm)	28.7	20.5	3.2	2.6 **
LG - MP (LPDH) (mm)	33.6	38.0	2.8	-1.6 *
Overbite (mm)	1.5	2.0	1.0	-0.5
<b>Soft Tissue Profile</b>				
Upper Lip to E-Plane (mm)	1.3	-4.0	2.0	2.6 **
Lower Lip to E-Plane (mm)	2.7	-2.0	2.0	2.4 **
STissue N Vert (True Vert) to Upper Lip (mm)	14.6	1.6	1.0	13.0 *****



## Post-Treatment:





**Pre-treatment:**

11

# **Post-Treatment:**

PERIODONTAL DIAGNOSIS AND TREATMENT PLAN																																				
PROBE RECORD	3	X	X	222	312	212	212	323	312	222	223	+	323	+	X	X	1	PROBE DATE	1	2	3	4	5	6	7	8	9	10	11	12	13	14	15	16		
	2	X	X	000	000	000	000	000	000	000	000	+	000	+	X	X																				
	1	X	X	222	312	212	212	323	312	222	223	+	323	+	X	X																				
F																	17	18	19	20	21	22	23	24	25	26	27	28	29	30	31	32				
	O																																			
		L																																		
PROBE RECORD	3		X	X	222	312	212	222	312	222	212	222	+	323	+	X	X	PROBE DATE	1	2	3	4	5	6	7	8	9	10	11	12	13	14	15	16		
	2	X	X	000	000	000	000	000	000	000	000	+	000	+	X	X																				
	1	X	X	222	312	212	222	312	222	212	222	+	323	+	X	X																				
SURG PLAN																	SURG PLAN	DATE	1	2	3	4	5	6	7	8	9	10	11	12	13	14	15	16		
	CENTRIC RELATION	<p>1 2 3 4 5 6 7 8 9 10 11 12 13 14 15 16</p> <p>32 31 30 29 28 27 26 25 24 23 22 21 20 19 18 17</p> <p>CR = CO <i>equilibrated to CO 2 mutually protruded articulation</i></p>																																	TMJ	
		RIGHT LATERAL	<p>1 2 3 4 5 6 7 8 9 10 11 12 13 14 15 16</p> <p>32 31 30 29 28 27 26 25 24 23 22 21 20 19 18 17</p>																																	HABITS
LEFT LATERAL	<p>1 2 3 4 5 6 7 8 9 10 11 12 13 14 15 16</p> <p>32 31 30 29 28 27 26 25 24 23 22 21 20 19 18 17</p>																TONGUE																			
PROTRU- SIVE	<p>1 2 3 4 5 6 7 8 9 10 11 12 13 14 15 16</p> <p>32 31 30 29 28 27 26 25 24 23 22 21 20 19 18 17</p>																	BRUXISM																		
																	OTHER																			
																		OPENING - M.M.	51 mm																	
PROBE RECORD	3	X	X	+	010	010	010	000	000	010	000	000	101	101	+	X	X	PROBE DATE	1	2	3	4	5	6	7	8	9	10	11	12	13	14	15	16		
	2	X	X	+	-1-1	-1-1	-1-1	-1-1	-1-1	-1-1	-1-1	-1-1	-1-1	-1-1	+	X	X																			
	1	X	X	+	121	121	212	111	111	212	111	112	212	212	+	X	X																			
F																	17	18	19	20	21	22	23	24	25	26	27	28	29	30	31	32				
	O																																			
		L																																		
PROBE RECORD	3		X	X	+	222	222	212	112	211	112	111	212	222	212	+	X	X	PROBE DATE	1	2	3	4	5	6	7	8	9	10	11	12	13	14	15	16	
	2	X	X	+	000	000	000	000	000	000	000	000	000	000	+	X	X																			
	1	X	X	+	222	222	212	112	211	112	111	212	222	212	+	X	X																			
SURG PLAN																	SURG PLAN	DATE	1	2	3	4	5	6	7	8	9	10	11	12	13	14	15	16		
	CENTRIC RELATION																																		TMJ	
		RIGHT LATERAL																																		HABITS
LEFT LATERAL																	TONGUE																			
PROTRU- SIVE																		BRUXISM																		
																	OTHER																			
																		OPENING - M.M.																		



## **PROBLEM LIST/DIAGNOSIS:**

### **A. CHIEF COMPLAINT**

- Pt presents with a primary chief complaint of “I have a gummy smile that I would like fixed.”
- Pt also states that “I would like some of my back teeth replaced, what about those implants.”
- Pt states hx of occasional, spontaneous discomfort #12
- Pt states hx of food impaction with discomfort between #28-29

### **B. MEDICAL/SYSTEMIC**

- ASA II
- BP 127/72 (7 Sept 10), 125/65 (23 Aug 10), 148/92 (26 Jul 10), 128/77 (8 Jun 10); Pulse 68; Resp.Rate 12; SpO2 99%; Temp. 98.8°
- Hx TIA 1999 due to thrombosis
- Dx HTN - controlled with medication
- Dx GERD - controlled with medication
- PSHx - Hysterectomy 2005
- Medications: Avalide 300/12.5mg, Nexium prn, Tylenol or Ibuprofen prn dental pain, hx ASA 81mg sporadically - pt states is now taking regularly
- Drug Allergy: Codeine-N/V (per pt, probable sensitivity), Ceftin-N/V (per pt, probable sensitivity), Morphine-urticaria, Paxil-urticaria
- No tobacco use
- No alcohol consumption

### **C. ORAL PATHOLOGY**

- Noted a 4x4mm well-circumscribed radiopacity #2 edentulous area with apparent normal trabeculation
  - DiffDx: idiopathic osteosclerosis, condensing osteitis, retained root
- Noted a 3x8mm well-circumscribed radiopacity resembling a retained root #15 edentulous area
  - DiffDx: Retained root, idiopathic osteosclerosis, condensing osteitis
- Noted a 1x2mm well-circumscribed radiopacity #1 mesial alveolar crest
  - DiffDx: Bony spicule/sequestrum, retained root
- Noted multiple, brown pigmented macules on the hard palate midline and posterior hard palate
  - DiffDx: Racial pigmentation, oral melanotic macule
- Noted a well-defined mixed radiopaque/radiolucent lesion #20 periapical area with apparent cortical rim
  - DiffDx: Focal osseous dysplasia, condensing osteitis, aberrant trabeculation

### **D. RESTORATIVE**

- Moderate caries risk
- Fair OH
- Apparent normal salivary flow and quality
- Gen., mild, max and man spacing/open contacts with max anterior diastemata
- Symptomatic open contact #28-29
- Incisal edge fracture #9
- #12 unsupported tooth structure and questionable restorability
- Dx: Carious dentition #1-O, #3-OL, #5-B, #12-MOL, #20-DO, #29-D

## **E. ENDODONTICS**

- No current RCT
- #12 positive to cold test (EndoIce®) with relative increase in sensitivity and lingering discomfort, slight percussion sensitivity, no palpation sensitivity; #12 caries near pulp
- Remaining dentition normal cold tests and no percussion sensitivity
- No periapical lesions
- Dx: #12 symptomatic irreversible pulpitis, symptomatic apical periodontitis

## **F. PERIODONTICS**

- Fair OH, pt states brushing 2x/day and occasional flossing
- Hx of sporadic prophylaxis and no hx of periodontal therapy
- Initial Modified O'Leary plaque index score = 63%
- Initial bleeding index/BOP = 14%
- Gen. mild plaque accumulation with mild interproximal calculus accumulation
- Pt appears motivated to improve OH especially after disclosing solution
- No probing depths >3mm
- No gingival recession
- Unable to definitively locate CEJ of dentition, noted to be subgingival
- Clinical attachment levels range from -1 to 3mm
- BOP #1, 7, 8, 9,10, 11, 12, 20, 21, 24, 25, 26, 27, 28
- Symptomatic open contact #28-29 with food impaction
- Seibert Class I #4 edentulous area and maxillary left posterior area
- Seibert Class III bilateral mandibular posterior area
- Excessive gingival display max anterior
- Potential unesthetic or non-ideal gingival contours bilateral max posterior with only max anterior esthetic crown lengthening
- Attached gingival height #6-11 ranges from 8-10mm
- Attached gingival height #3, 5, 12, and 13 ranges from 3.5-5mm
- Potential insufficient interdental papilla and presence of „black triangles“ with esthetic crown lengthening maxillary anterior
- Potential biologic width/dentogingival complex compromise #12 mesial
- Dx: Gen. plaque-induced gingivitis
- Dx: Excessive gingival display maxillary anterior due to altered passive eruption

## **G. OCCLUSION AND TMJ**

- No TMJ issues, range of motion limitations, or significant deviations/deflections
- CR does not equal MIP with 1<sup>st</sup> point of contact #3-29
- 1mm anterior shift from CR 1<sup>st</sup> point of contact to MIP
- Apparent bilateral group function occlusion in lateral excursive movements
- Supraeruption #1, 3 with #1 nearly occluding on max alveolar ridge
- MIO=51mm
- Decreased interarch space right posterior
- Bilateral posterior mild occlusal attrition with wear facets

## **H. ORAL SURGERY**

- #1 no apical proximity to max sinus nor root anomalies
- #12 no apical proximity to max sinus, two roots
- Apparent adequate alveolar bone height max bilateral edentulous posterior area with no max sinus proximity



- adequate alveolar bone height man bilateral edentulous posterior area ; no IAN proximity

## I. ORTHODONTICS

- Angle Class I bilateral canine, no molar occlusion
- Anteriorly divergent profile with acute nasolabial angle
- Vertical facial third lengths approximately equivalent
- Gen., mild, max and man spacing
- Max arch excess space=7.9mm
- Man arch excess space=3.5mm
- #6-11 excess space =3.8mm
- Overjet=2.5-3mm, Overbite=50%
- Max midline to right 1mm from facial midline
- Man midline to left 2mm from max midline
- Supraeruption #1, 3
- Mesial angulation #3

## J. PROSTHODONTICS

- CR does not equal MIP
- 1mm anterior shift from CR 1<sup>st</sup> point of contact to MIP
- Apparent bilateral group function occlusion in lateral excursive movements
- Decreased interarch space right posterior
- Inadequate posterior occlusion, no molar occlusion
- Inadequate interarch space bilaterally for 2<sup>nd</sup> molar occlusion
- No posterior molar abutments max left and man bilateral
- Seibert Class I #4 edentulous area and maxillary left posterior area
- Seibert Class III bilateral mandibular posterior area
- Adequate vertical stops on premolars
- Good crown:root ratio of dentition
- Good abutments #3, 5, 11, 13, 20, 29 for potential fixed or removable prosthesis
- Supraeruption #3 into occlusal plane
- Mesial inclination #3 with loss of space #4 edentulous area
- Undermined tooth structure #12 and questionable restorability
- Decreased clinical crown height max anterior with esthetic concerns
- Restore/replace # 4, 12, 14, 19, and 30 with a prostheses and/or implants

## K. ESTHETICS

- Pt desires decreased gingival display max anterior upon smiling
- Gen mild, max and man spacing/open contacts with max anterior diastemata
- Slight reverse smile right posterior due to supraeruption #3
- Upper lip length = 25mm
- Excessive gingival display due to altered passive eruption
- Max anterior teeth dimensions:

	Height (mm)	Width (mm)	H:W Ratio
#6	8.1	7.9	1.03 : 1
#7	6.4	7.5	0.85 : 1
#8	8.3	8.9	0.93 : 1
#9	7.5	8.9	0.84 : 1
#10	7.2	7.5	0.96 : 1
#11	8.9	8.1	1.10 : 1

## **TREATMENT OBJECTIVE OVERVIEW:**

- The patient is ASA II with no significant contraindications to dental treatment
- Monitor the patient's HTN control throughout dental treatment
- Treatment will be provided utilizing evidence-based dentistry principles to restore the patient to optimal oral health, function, comfort, and esthetics
- A diagnostic mounting and waxing in CR will be completed to evaluate and provide a guide for the dental treatment plan – beginning with the end in mind
- The dental treatment plan will address the patient's chief complaint of excessive maxillary gingival display with an esthetic crown lengthening procedure
- The dental treatment plan will also address the patient's chief complaint of inadequate posterior occlusion with implant-supported crowns restored to first molar occlusion
- The patient will be restored in CR/CO with a mutually protected articulation occlusal scheme
- Discuss OHI and nutritional/dietary counseling to ensure patient understands etiology of disease and prevention of disease reoccurrence
- Eval the OH status via the Modified O'Leary plaque index
- Oral prophylaxis and operative treatment to eliminate sources of infection and caries
- Evaluate and determine restorability #12; Assuming #12 non-restorable plan to extract with ridge preservation
- The patient will then be re-evaluated to assess the progression of the treatment plan according to the patient's chief complaint, desire to continue with proposed treatment plan, and response to preparatory/diagnostic/disease control phase
- Obtain CBCT with radiographic guides to evaluate potential implant sites #4, 12, 14, 19, 30 and need for bone grafts
- Limited orthodontic treatment including temporary anchorage devices (TADs) to intrude and rotate/translate #3 distally making adequate restorative space for implant-supported crowns #4, 30
- Esthetic crown lengthening of the maxillary arch due to altered passive eruption
- Placement of endosseous implants #4, 12, 14, 19, 30
- Equilibration to CR following occlusal device therapy
- Direct composite restorations #9 ILF for enamel fracture, #10-11 for diastema closure, and #29 M for closure of open contact to prevent food impaction
- Delivery of implant-supported POM crowns with custom abutments #4, 12, 14, 19, 30
- Fabricate occlusal device in CR
- Oral prophylaxis, implant, pathology, and occlusal device recalls/maintenance

## **TREATMENT PLAN WITH RATIONALE:**

### **A. EMERGENT PHASE**

<b>Treatment</b>	<b>Rationale</b>
-No treatment indicated	-N/A

### **B. SYSTEMIC/MEDICAL PHASE**

<b>Treatment</b>	<b>Rationale</b>
-Monitor the patient's BP; avoid long-term NSAID therapy	-Dx HTN controlled with medication, monitor HTN control and refer to physician as needed -Long-term NSAID therapy potential antagonist to HTN control and ASA therapy
-Limit dose/eval response to opioids	-Hx N/V to codeine, sensitivity to opioids
-Avoid 2 <sup>nd</sup> generation cephalosporin antibiotics, limit dose/eval response to penicillin-type and 1 <sup>st</sup> generation cephalosporins	-Hx N/V to Cefitin, sensitivity to 2 <sup>nd</sup> generation cephalosporins; 1-7% crossreactivity between penicillin-type antibiotics and cephalosporins
-Avoid morphine-containing opioids; limit dose/eval response to opioids	-Hx urticaria to morphine
-Avoid Paxil; limit dose/eval response to SSRIs	-Hx urticaria to Paxil
-Evaluate the multiple, brown pigmented macules on the hard palate midline/posterior hard palate for changes, the radiopacities in #2, 15 edentulous areas for changes, and the mixed radiopaque/radiolucent lesion #20 apical area for changes on a regular basis throughout the treatment	-DiffDx of pathology noted is not significant and no tx is indicated other than regular follow-up and eval for changes

### **C. PREPARATORY/DIAGNOSTIC/DISEASE CONTROL PHASE**

<b>Treatment</b>	<b>Rationale</b>
-Comprehensive oral eval; periodontal charting	-Documentation of existing restorations, defective restorations, caries, periodontal status of dentition, oral cancer screening, and additional findings to develop problem list
-Max/man diagnostic alginate impressions; duplicate x 3; pour master casts in Type V dental stone and duplicates in Type IV dental stone	-Alginate: aqueous hydrocolloid; inexpensive, readily available, ease of use, good accuracy, sets quickly, hydrophilic, compatible with gypsum -Type V dental stone: excellent compressive strength -Type IV dental stone: less expansion (0.09%) than Type V, good compressive strength -Diagnostic casts used for diagnosis and tx planning, diagnostic waxing, radiographic guides/surgical stents, record bases



-CR record and protrusive record	<ul style="list-style-type: none"> <li>-CR record made using leaf gauge and tongue to posterior palatal position technique: easy to adjust leaf gauge; objective evaluation of OVD; physiologic, repeatable, consistent, comfortable; deprogram neuromuscular apparatus</li> <li>-Protrusive record can be used to program condylar guidance/inclination on a Celenza Class 3b, Arcon, semi-adjustable articulator; safer record resulting in less steep/more shallow condylar inclination</li> <li>-Regisil PB used to make CR record and protrusive record due to accuracy, quick set, strength, not restrictive to mandibular movement, and ability to be trimmed/adjusted</li> </ul>
-Facebow transfer	<ul style="list-style-type: none"> <li>-Records and transfers the position of the maxillary arch relative to the cranial base and horizontal axis of rotation to an articulator</li> </ul>
-Intraoral and extraoral clinical photos	<ul style="list-style-type: none"> <li>-Documentation of pre-treatment oral status and to develop problem list; adjunct to develop tx plan</li> </ul>
-Full-mouth series digital radiographs; panoramic digital radiograph; lateral cephalometric radiograph	<ul style="list-style-type: none"> <li>-Documentation of hard tissue status, existing restorations, defective restorations, caries, periodontal status of dentition, endodontic status of dentition, pathology</li> <li>-Lateral cephalometric radiograph to eval skeletal and dental relationships prior to orthodontic tx</li> </ul>
-Diagnostic mounting in CR on Celenza Class 3b, Arcon, semi-adjustable articulator (Whip-Mix); program articulator with the protrusive record	<ul style="list-style-type: none"> <li>-Diagnostic mounting used for simulation of jaw movements, analysis of occlusal plane, analysis of occlusion/disclusion, visualization of anatomy and restorations, analysis of abutment length/angulation, diagnostic preparations, analysis of restorative space, morphology of tissue and edentulous ridges, and analysis of edentulous spans</li> <li>-Simulates physiologic mandibular movement substituting mechanical equivalents for anatomic parts</li> <li>-Accepts facebow transfer and 80% of records where 75% of population is within 6mm of true horizontal hinge axis of rotation; protrusive record used to set condylar guidance/inclination using an average of 7 for Bennett angle/laterotrusion</li> <li>-Displays none-minimal arc of closure error in CR (condylar inclination and max occlusal plane angle remains the same with change in OVD)</li> <li>-Used for fixed and removable prostheses fabrication</li> </ul>
-3-piece cast analysis	<ul style="list-style-type: none"> <li>-Allows for analysis of instant equilibration, eval of anterior-posterior coupling, eval of mutually-protected articulation, and reasonableness of restoring in CR</li> <li>-Diagnostic equilibration to CR</li> </ul>
-Diagnostic waxing in CR	<ul style="list-style-type: none"> <li>-Evaluate occlusal plane and occlusion/disclusion of proposed tx plan</li> <li>-Evaluate anatomic contours of proposed tx plan</li> <li>-CR with a mutually-protected occlusal scheme eliminates eccentric interferences, decreases trauma from occlusion (attrition/cusp fractures), develops class 3 lever where anterior disclusion is anterior to muscles generating less force, stabilizes occlusion, interrupts potentially destructive forces to TMJ, and is a repeatable position</li> </ul>

-Present and review the treatment plan with patient	- Gains patient acceptance and understanding according to the their chief complaint and desires
-Oral prophylaxis with supragingival scaling; fluoride treatment with 5% NaF varnish; continue to eval the OH status via the Modified O'Leary plaque index and assess bleeding index; discuss OHI and nutritional/dietary counseling; Rx: Prevident 5000 Plus dentifrice, brush teeth bid with pea-sized amount, expectorate	<ul style="list-style-type: none"> <li>-Ensure patient understands etiology of disease process and prevention of disease reoccurrence</li> <li>-Removal of plaque/calculus to reduce oral bacterial load and the reservoir/niche for oral bacteria and/or toxins</li> <li>-Modified O'Leary plaque index to ensure patient displays adequate plaque removal, goal <math>\geq 80\%</math></li> <li>-Assess bleeding index, <math>&lt;10\%</math> considered gingival health</li> <li>-Ensure low and infrequent carbohydrate/refined sugar consumption</li> <li>-Fluoride treatment with Vanish 5% NaF varnish; ease of handling, slowly dissolved by saliva, high-dose fluoride (22,500ppm), inhibits bacterial metabolism, inhibits demineralization, enhances remineralization</li> <li>-Fluoride treatment with Prevident 5000 Plus dentifrice; ease of use, consistent fluoride exposure (5000ppm), inhibits bacterial metabolism, inhibits demineralization, enhances remineralization</li> </ul>
-Operative tx #3 OL amalgam	<ul style="list-style-type: none"> <li>-#3 recurrent caries</li> <li>-Valiant Ph.D amalgam: admixture of lathe-cut and single composition spherical; high copper amalgam nearly eliminating Gamma 2 phase; contains palladium for early strength and reinforce gamma 1 phase; fine particle size for a dense set; ease of use and condensability</li> </ul>
-Operative tx #5 B composite	<ul style="list-style-type: none"> <li>-#5 carious lesion</li> <li>-Optibond FL DBA: 4<sup>th</sup> generation, 3 step Etch and Rinse; 97% retention at 13 yrs, gold-standard for DBA; separate primer and adhesive; 48% filled with good bond strengths and less microleakage; radiopaque; use 37.5% phosphoric acid etch</li> <li>-Filtek Supreme Ultra composite: nanocomposite; 78% filled by weight; good strength, good wear resistance, and good esthetics/polishability; universal use for both anterior and posterior restorations; nanoclusters wear similar to adjacent resin matrix and are smaller than microfilled formed silica</li> <li>-Cure using a 3<sup>rd</sup> generation LED dual-emission spectrum light; ease of use, efficient light, longevity; reportedly able to cure camphorquinone, PPD, and TPO photoinitiators</li> </ul>
-Operative tx #20 DO amalgam, M pit composite	<ul style="list-style-type: none"> <li>-#20 carious lesions</li> <li>-Amalgam, DBA, and composite as previously noted</li> </ul>
-Operative tx #29 D composite	<ul style="list-style-type: none"> <li>-#29 carious lesion</li> <li>-DBA and composite as previously noted</li> </ul>

-Eval restorability #12; Extraction #12 with ridge preservation	-Extraction #12 due to following reasons: biologic width/dentogingival complex compromise (<3mm) on mesial resulting in a 1:1 crown root ratio post crown lengthening; insufficient tooth structure for ferrule (1-2mm) resulting in less retention for indirect restoration -Ridge preservation recommended for alveolar bone width post extraction <2mm to maintain ridge width -Bio-Oss Collagen bone graft: bovine bone combined with 10% porcine collagen; osteoconductive, ease of use, does not require membrane, does not require 2 <sup>nd</sup> surgical site; allow 6 months prior to implant placement -Rx: 500mg Amoxicillin q8h for 7 days; recommend systemic antibiotic to prevent infection of bone graft
-2% lidocaine with 1:100,000 epi local anesthetic	-Good efficacy, low allergic reaction, 60-90min pulpal and 3-4hrs soft tissue anesthesia -Use for routine and invasive/surgical procedures
-0.5% bupivacaine with 1:200,000 epi local anesthetic	-Good efficacy, high lipid solubility and protein binding resulting in 90-180 pulpal and 8hrs soft tissue anesthesia -Use for routine and invasive/surgical procedures where longer anesthesia is desired
-Rubber dam	-Isolation improves access, moisture control, reduces contamination, retraction of tissue, and color contrast -Use for operative procedures
-Rx: Ibuprofen 600mg q8h for 3-5 days prn pain	-Anti-inflammatory, decreased prostaglandin production, analgesic, good efficacy for oral pain -Rx for more invasive/surgical dental treatment procedures
-Rx: 0.12% chlorhexidine rinse bid for 2 weeks, expectorate	-Antimicrobial rinse, binds to bacterial cell wall and disrupts osmotic balance, decreases plaque accumulation -Recommend antimicrobial agent and plaque reduction of implant surgical site until epithelial healing has occurred -Rx for use following invasive/surgical procedures
-Rx: 500mg amoxicillin q8h for 7 days	-Inhibits bacterial cell wall synthesis, extended spectrum to include gram negative and/or mixed infections of oral origin, attains high plasma levels -Recommend systemic antibiotic to prevent infection of bone graft -Rx following bone graft procedures
-Rx: 2g amoxicillin 1 hr prior to procedure	-As previously noted -Rx as prophylactic antibiotic for primary endosseous implant placement

#### D. RE-EVALUATION PHASE

Treatment	Rationale
-Evaluate the OH status via the Modified O'Leary plaque index; discuss OHI and dietary counseling	-Ensure patient is maintaining good OH to eliminate and prevent the disease process
-Evaluate the corrective/restorative treatment plan following the preparatory/diagnostic/disease control phase	-Evaluate the patient response to the preparatory/diagnostic/disease control phase and ensure is conducive to the corrective/restorative treatment plan -Ensure the patient desires to continue with the proposed treatment plan



## E. CORRECTIVE/RESTORATIVE PHASE

Treatment	Rationale
-Mountings completed in CR on Celenza Class 3b, Arcon, semi-adjustable articulator (Whip-Mix)	-As previously noted
-Obtain CBCT for potential implant sites #4, 12, 14, 19, 30 with radiographic guide in place -Evaluate 3-dimensional osseous structure relative to proposed implant site angulation and restoration; evaluate adequate bone present and need for bone graft	-Radiographic guide fabricated based on dx waxing -CBCT in iCAT with following settings: 16cm x 6cm, 0.2 voxel, 14.7sec – higher resolution, smaller FOV, less radiation exposure
-Limited orthodontic tx /TAD placement #3	-Place band on #3 and B/L buttons on #1 -Mondeal Lomas Quattro 1.5x7mm TADs to provide sufficient anchorage to move #3 distally and intrude -Utilize #1 as additional anchorage to move #3 distally
-Orthodontic follow-up appointments q 2-4 weeks for 6 months; max essix-type retainer	-Change closed powerchains q2-4 weeks to maintain consistent, low force/pressure -Monitor movement #3 -Fabricate 2mm thick essix-type retainer to maintain position #3 until implant-supported crowns delivered
-Stage I endosseous implant placement #19 with bone graft/membrane	-Biomet3i, Full Osseotite Certain 4x11.5mm implant: titanium alloy, acid-etched surface promotes osseointegration to implant platform, internal hex, internal anti-rotation -Autogenous bone graft: osteogenic, osteoinductive, osteoconductive; placed adjacent to implant -Bio-Oss bone graft: bovine bone graft; osteoconductive; placed adjacent to autogenous bone graft; ease of use, maintains space well, does not require 2 <sup>nd</sup> surgical site -OsseoGuard membrane: resorbable bovine collagen membrane, resorption in approximately 26-38 weeks -Bone graft/membrane necessary for minimal 1-2mm thickness buccal bone adjacent to implant -Use surgical stent converted from radiographic guide to place implant at correct angulation and position determined from dx waxing -Place implant platform approximately 3-4mm apical to adjacent teeth buccal CEJ to allow for normal emergence profile and esthetics
-Stage I endosseous implant placement #30	-Biomet3i, Full Osseotite Certain 4x11.5mm implant: titanium alloy, acid-etched surface promotes osseointegration to implant platform, internal hex, internal anti-rotation -Use surgical stent converted from radiographic guide to place implant at correct angulation and position determined from dx waxing -Place implant platform approximately 3-4mm apical to adjacent teeth buccal CEJ to allow for normal emergence profile and esthetics

-#5-11 esthetic crown lengthening	<ul style="list-style-type: none"> <li>-Excessive gingival display due to altered passive eruption</li> <li>-Position the gingival margin #5-11 in a more apical position at the CEJ</li> <li>-Osteoplasty and ostectomy to achieve 3mm between CEJ and coronal position of alveolar bone</li> <li>-#5-11 buccal/facial flap reflection only preserving lingual papilla to decrease risk of post-op recession and formation of black triangles</li> </ul>
-1, 2, 4, 8 week POT for #5-11 esthetic crown lengthening	-Evaluate for normal healing and plaque removal
-Stage I endosseous implant placement #4; crown lengthening #3; extraction #1	<ul style="list-style-type: none"> <li>-Biomet3i, Full Osseotite Certain 4x11.5mm implant: titanium alloy, acid-etched surface promotes osseointegration to implant platform, internal hex, internal anti-rotation</li> <li>-Use surgical stent converted from radiographic guide to place implant at correct angulation and position determined from dx waxing</li> <li>-Place implant platform approximately 3-4mm apical to adjacent teeth buccal CEJ to allow for normal emergence profile and esthetics</li> </ul>
-Stage I endosseous implant placement #12 and 14; crown lengthening #13	<ul style="list-style-type: none"> <li>-#12 Biomet3i, Full Osseotite Certain 4x11.5mm and #14 Biomet3i, Full Osseotite Certain 5x11.5mm implants: titanium alloy, acid-etched surface promotes osseointegration to implant platform, internal hex, internal anti-rotation</li> <li>-Use surgical stent converted from radiographic guide to place implant at correct angulation and position determined from dx waxing</li> <li>-Place implant platform approximately 3-4mm apical to adjacent teeth buccal CEJ to allow for normal emergence profile and esthetics</li> </ul>
-1, 2, 4, 8 week POT for stage I implant placements	-Evaluate for normal healing and plaque removal
-Max/man alginate impressions; occlusal device record; fabricate occlusal device in CR	<ul style="list-style-type: none"> <li>-Fabricate max occlusal device using Ortho-Jet PMMA acrylic in CR and adjust to achieve mutually-protected articulation</li> <li>-Occlusal device record made in CR position open 2-3mm for adequate thickness of acrylic</li> <li>-Regisil PB used to make occlusal device record as previously noted</li> </ul>
-Occlusal device therapy for CR equilibration	<ul style="list-style-type: none"> <li>-Use of occlusal device therapy in CR to evaluate patient response to new mandibular position; evaluate patient comfort and function in CR position prior to irreversible CR equilibration</li> <li>-Allows for reversible treatment to a CR position with mutually-protected articulation</li> </ul>
-CR equilibration following occlusal device therapy	<ul style="list-style-type: none"> <li>-CR with a mutually-protected occlusal scheme eliminates eccentric interferences, decreases trauma from occlusion (attrition/cusp fractures), develops class 3 lever where anterior disclusion is anterior to muscles generating less force, stabilizes occlusion, interrupts potentially destructive forces to TMJ, and is a repeatable position</li> <li>-Complete CR equilibration of dentition following occlusal device therapy</li> </ul>

-Operative tx #9 ILF	-#9 ILF enamel fracture -DBA and composite as previously noted
-Operative tx #10 DLF, 11 MLF	-#10-11 diastema, previously unrestored dentition, minimally invasive treatment ideal -DBA and composite as previously noted
-Operative tx #29 M interproximal	#28-29 open contact with symptomatic food impaction, previously minimally restored dentition, minimally invasive treatment ideal -DBA and composite as previously noted
-Stage II implant surgery for healing abutment placement #4, 12, 14, 19, 30	-#4, 12, 19, 30 Biomet3i Encode 4.1/5/4mm and #14 Biomet3i Encode 5/6/4mm healing abutments -Verified healing abutment seating via radiographs -Placement of healing abutments with slightly wider emergence profile -Position gingival margins with minimal 2mm band/collar of keratinized gingival tissue around healing abutment
-1, 2, 4 week POT for stage II implant surgery	-Evaluate for normal healing and plaque removal
-Implant level impression #4, 12, 14, 19, 30	-Extrude VPS impression material: addition silicone; no by-product and therefore very dimensionally stable, good accuracy, improved wettability, thixotropic properties, compatible with gypsum -Open tray impression technique: allows impression coping to remain in impression material, less potential for error -Verified impression coping seating via radiographs -Allows for accurate reproduction of implant position relative to adjacent dentition
-Custom abutment try-in #4, 12, 14, 19, 30; CR record	-Jelenko Firmilay II type III gold custom abutments (73% Au) -Verified custom abutment seating via radiographs -Gold custom abutments allow for customization of emergence profile and margin location -Gold custom abutments result in a more pleasant, warm tone to underlying gingival tissue -Regisil PB used to make CR record as previously noted
-Delivery of custom abutments and implant-supported POM crowns #4, 12, 14, 19, 30	-Biomet 3i Certain Gold-Tite hexed screw torqued to 20N-cm -Verified impression coping seating via radiographs -Abutment access sealed with 0.12% CHX-soaked pellet and composite as previously noted -Cement using RelyX Luting Plus: RMGI cement; good tensile and compressive strength, ease of use, low microleakage, low solubility, low film thickness -POM crown fabricated from Olympia high noble metal (51.5% Au, 38.5% Pd) and IPS InLine PoM ceramic; POM ceramic uses lost-wax technique with improved ability to control occlusion and contours

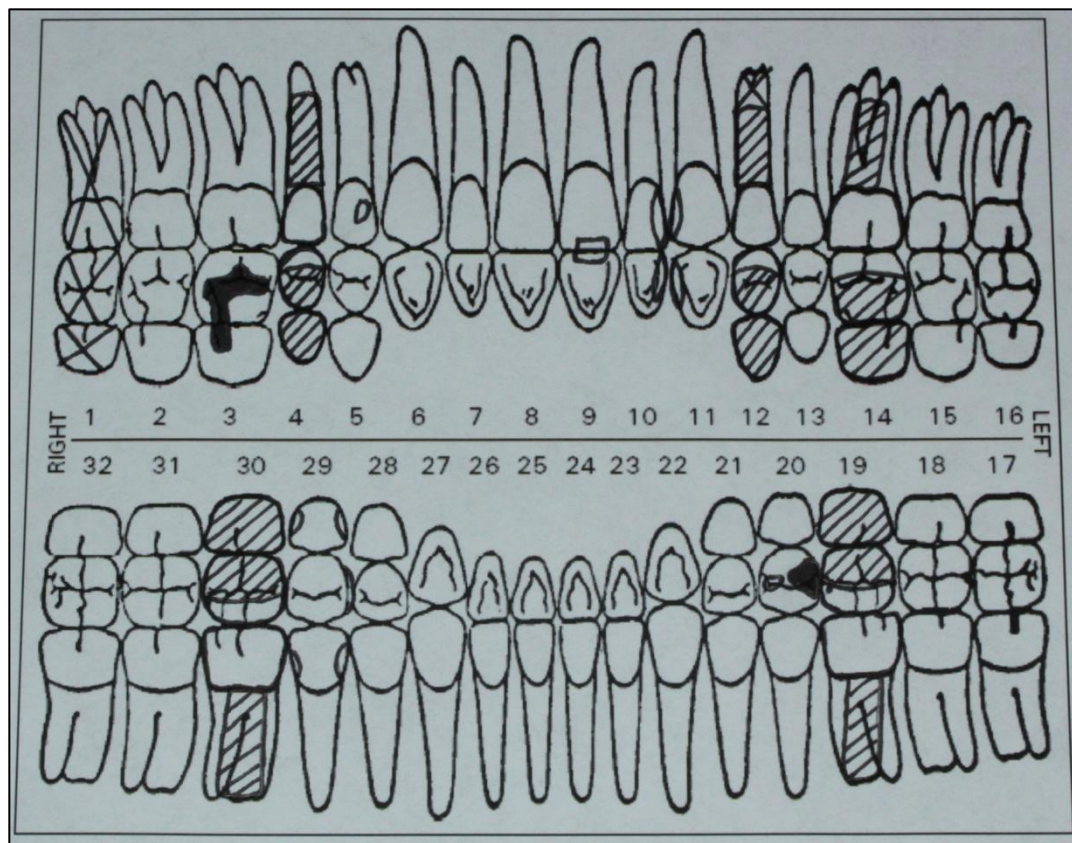


-Max/man alginate impressions; occlusal device in CR; fabricate occlusal device in CR	-Alginate impressions as previously noted -Fabricate max occlusal device using Eclipse resin-type material: less volumetric shrinkage than PMMA acrylics (3% vs 7%), ease of use, handles like wax, improved ability to control occlusion -Regisil PB used to make occlusal device record as previously noted
-Delivery max occlusal device in CR	-Occlusal device in CR as previously noted

## F. MAINTENANCE PHASE

Treatment	Rationale
-Oral prophylaxis q 6 months; fluoride treatment with 5% NaF varnish; continue to eval the OH status via the Modified O'Leary plaque index and assess bleeding index; discuss OHI and nutritional/dietary counseling	-As previously noted
-Implant maintenance/recall and oral pathology recall q 12 months	-Evaluate gingival health/response and osseous structure/bone levels of implant; evaluate crown and abutment integrity -Evaluate/monitor changes of previously noted oral pathology lesions
-Occlusal device recall q 6 months	-Evaluate fit and occlusion/discussion to ensure a mutually-protected articulation occlusal scheme is maintained

## Charting Of Treatment Rendered:



### Prognosis:

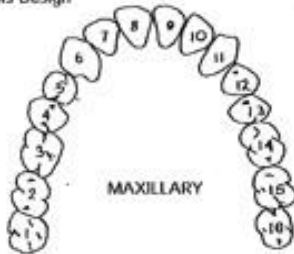
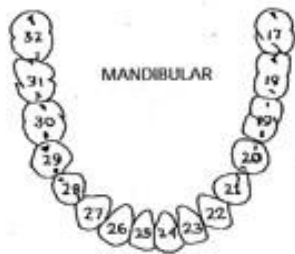

- Periodontal prognosis is good
- Restorative prognosis is good
- Esthetic prognosis is good with the ability to apically position the maxillary gingival margin via esthetic crown lengthening, closing the diastemata with direct composite restorations, and replacing the missing maxillary teeth with implant-supported crowns
- Prosthetic/occlusal prognosis is good with the ability to attain first molar occlusion with implant-supported crowns in CR with mutually-protected articulation and use of an occlusal device

### Medical/Specialty Consults:

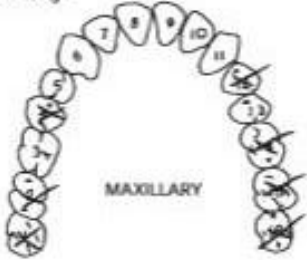


- N/A

### PROSTHODONTIC LAB WORK AUTHORIZATIONS:

#### Max/Man Dx Casts

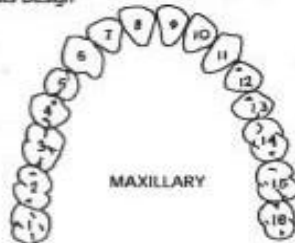
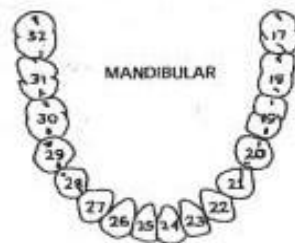

12. Type of Prosthesis or Restoration Dx impressions and duplication		13. Shade and Mold by Guide	14. Date Delivered
15. Prosthesis Design			
 MAXILLARY		 MANDIBULAR	
Request(s) (Check appropriate box(es))		16. <input type="checkbox"/> Framework Only	17. <input type="checkbox"/> Set-up
18. <input type="checkbox"/> Process	19. <input type="checkbox"/> Fully Fabricate	20. <input type="checkbox"/> Bisque Bake	21. <input type="checkbox"/> Consultation
22. <input type="checkbox"/> Diagnostic Casts		23. <input type="checkbox"/> Jaw Relation Record	24. <input type="checkbox"/> Radiographs
25. <input type="checkbox"/> Other (See remarks)			
26. Clinician's Remarks/Instructions			
<p>1. Please pour max/man dx impressions in die keen stone, two-step pour, and pin for mounting.</p> <p>2. Please duplicate max/man casts and pour in die keen stone, two-step pour, and pin for mounting.</p> <p>Thank you.</p>			
27. Typed Name and Grade of Dental Officer NBDuVall, Maj		28. Signature 	
DD Form 2322, OCT 83		Dental Laboratory Work Authorization	

## #4, 12, 14, 19, 30 Custom Abutments

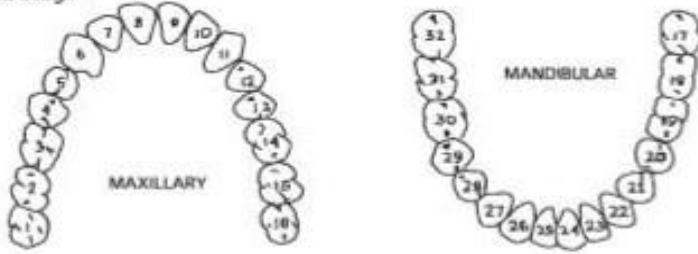

12. Type of Prosthesis or Restoration #4, 12, 14, 19, 30 custom abutments	13. Shade and Mold by Guide	14. Date Delivered
15. Prosthesis Design <div style="display: flex; justify-content: space-around; align-items: center; margin-top: 10px;">   </div>		
Request(s) (Check appropriate box(es))		
16. <input type="checkbox"/> Framework Only		
17. <input type="checkbox"/> Set-up		
18. <input type="checkbox"/> Process		
19. <input type="checkbox"/> Fully Fabricate		
20. <input type="checkbox"/> Bisque Bake		
21. <input type="checkbox"/> Consultation		
22. <input type="checkbox"/> Diagnostic Casts		
23. <input type="checkbox"/> Jaw Relation Record		
24. <input type="checkbox"/> Radiographs		
25. <input type="checkbox"/> Other (See remarks)		
26. Clinician's Remarks/Instructions <p>Please fabricate type 3 gold custom abutment for #4, 12, 14, 19, 30 implants:</p> <ol style="list-style-type: none"> <li>1. Please pour max/man VPS impressions in die-keen stone with a base, 2 step pour. Return to me for orientation/mounting.</li> <li>2. Complete full contour waxing of for PFM crowns with final margins following gingival contours with supplied UCLA abutment. Return to me for eval.</li> <li>3. Complete cutback for custom abutments and fabricate custom abutments with type 3 gold. Return to me for eval and interocclusal record.</li> </ol> <p>Thank you.</p>		
27. Typed Name and Grade of Dental Officer Maj DuVall		28. Signature 
DD Form 2322, OCT 83		Dental Laboratory Work Authorization



## #4, 12, 14, 19, 30 Implant-Supported POM Crowns

12. Type of Prosthesis or Restoration #4, 12, 14, 19, 30 Implant POM crowns	13. Shade and Mold by Guide Vita Classic A1	14. Date Delivered
15. Prosthesis Design <div style="display: flex; justify-content: space-around; align-items: center; margin-top: 10px;">  <div style="text-align: center;"> <p>MANDIBULAR</p>  </div> </div>		
Request(s) (Check appropriate box(es)) <div style="display: flex; justify-content: space-between; margin-top: 5px;"> <span>15. <input type="checkbox"/> Framework Only</span> <span>17. <input type="checkbox"/> Set-up</span> </div> <div style="display: flex; justify-content: space-between; margin-top: 5px;"> <span>18. <input type="checkbox"/> Process</span> <span>19. <input type="checkbox"/> Fully Fabricate</span> <span>20. <input type="checkbox"/> Bisque Bake</span> <span>21. <input type="checkbox"/> Consultation</span> </div>		
22. <input type="checkbox"/> Diagnostic Casts            23. <input type="checkbox"/> Jaw Relation Record            24. <input type="checkbox"/> Radiographs            25. <input type="checkbox"/> Other (See remarks)		
26. Clinician's Remarks/Instructions <p>Please fabricate #4, 12, 14, 19, 30 implant-supported crowns as follows:</p> <ol style="list-style-type: none"> <li>1. Apply 3 coats of die spacer to custom gold abutments. Make dupe dies with silky rock.</li> <li>2. Complete full-contour waxing #4, 12, 14, 19, 30 crowns using matrix provided from previous full-contour waxing. Return to me for eval.</li> </ol> <p>***Use max/man casts with custom gold abutments for final margin waxing. Verify interproximal contacts and occlusal contacts on max/man casts with die-keen stone abutments.***</p> <ol style="list-style-type: none"> <li>3. Complete cut-back according to fixed design PD-4 with disappearing buccal/interproximal metal margin. B/C contacts on metal. Return for eval.</li> <li>4. Fabricate #4, 12, 14, 19, 30 POM crowns with a high noble alloy. Finish and polish. Thank you.</li> </ol>		
27. Typed Name and Grade of Dental Officer Maj N. DuVall	28. Signature <div style="text-align: center; margin-top: 10px;">  </div>	
DD Form 2322, OCT 83 <div style="text-align: right; margin-top: 5px;"> <small>Dental Laboratory Work Authorization</small> </div>		

## Max Eclipse Occlusal Device

12. Type of Prosthesis or Restoration Max occlusal device - Eclipse	13. Shade and Mold by Guide	14. Date Delivered
15. Prosthesis Design		
		
Request(s) (Check appropriate box(es)) <div style="display: flex; justify-content: space-between;"> <div>16. <input type="checkbox"/> Framework Only</div> <div>17. <input type="checkbox"/> Set-up</div> </div> <div style="display: flex; justify-content: space-between;"> <div>18. <input type="checkbox"/> Process</div> <div>19. <input type="checkbox"/> Fully Fabricate</div> <div>20. <input type="checkbox"/> Bisque Bake</div> <div>21. <input type="checkbox"/> Consultation</div> </div> <div style="display: flex; justify-content: space-between;"> <div>22. <input type="checkbox"/> Diagnostic Casts</div> <div>23. <input type="checkbox"/> Jaw Relation Record</div> <div>24. <input type="checkbox"/> Radiographs</div> <div>25. <input type="checkbox"/> Other (See remarks)</div> </div>		
26. Clinician's Remarks/Instructions <p>Please fabricate a max Eclipse occlusal device as follows:</p> <ol style="list-style-type: none"> <li>1. Zero degree block-out on max cast</li> <li>2. Follow design on master cast to shape Eclipse to achieve full arch contacts in CO/mutually-protected articulation with anterior disocclusion, just enough ramp to allow clearing of man posterior teeth in lateral moves.</li> <li>3. Complete occlusal contacts prior to removal from cast. Finish/polish.</li> </ol> <p>Thank you.</p>		
27. Typed Name and Grade of Dental Officer Maj N DuVall		28. Signature 
DD Form 2322, OCT 83		Dental Laboratory Work Authorization 