Clinical Chemistry 65:6
733–738 (2019)

Clinical Case Study

Not Your Ordinary Rash

Grace R. Williams[1,2] and Robert D. Nerenz[1,2*]

CASE DESCRIPTION

A 17-year-old, 6-week pregnant female presented to the emergency department with symptoms of abdominal pain, nausea, and vomiting for 2 days. Although she initially complained of only low right abdominal pain, by the next day, she complained of a generalized abdominal ache. Laboratory values upon admission included a plasma sodium concentration of 118 mmol/L, potassium of 3.0 mmol/L, and chloride of 80 mmol/L. On the third day of admission, she experienced 2 seizures. She denied previous history of seizures or other neurological diseases, but she did have a long history of "eczema-like" rashes on her face, neck, and hands that had been unresponsive to prednisone. A urine drug screen was negative, and physical examination was unremarkable. On review of her chart, it was noted that 6 months before her hospital admission, the patient had consulted a dermatologist who described numerous small eroded papules and scarring on the back of the patient's hands, neck, and upper chest. Urine and plasma specimens collected during this dermatology appointment had been sent to a reference laboratory for porphyrin fractionation and porphobilinogen (PBG)[3] measurement. Results are presented in Table 1. Because of the patient's symptoms upon presentation to the emergency department and previously increased urine PBG concentration, she was treated with daily hemin infusions for 4 days and her symptoms resolved. Over the consequent 2 days, her plasma sodium concentration increased to 135 mmol/L and she was discharged.

DEFECTIVE HEME SYNTHESIS

The porphyrias are a group of metabolic disorders caused by functional alterations in the enzymes responsible for heme synthesis, resulting in the accumulation of heme precursors. Porphyrias are categorized as either acute or cutaneous, and presenting symptoms are defined by the enzymatic defect and the properties of the accumulated heme intermediate *(1)*. (Fig. 1) These categories are not mutually exclusive, as patients with variegate porphyria (VP) and hereditary coproporphyria (HCP) may experience both acute neurovisceral and cutaneous symptoms.

QUESTIONS TO CONSIDER

1. What are some causes of concurrent hyponatremia and abdominal pain?
2. How would acute porphyria be differentiated from other conditions with a similar clinical presentation?
3. Why did the patient's symptoms resolve following hemin infusion?
4. How should molecular testing be integrated into the further workup of this patient?

ACUTE PORPHYRIAS

Patients with acute porphyria [acute intermittent porphyria (AIP), VP, HCP, and delta-aminolevulinic acid dehydratase deficient porphyria (ADP)] can present with a life-threatening neurovisceral crisis, typically characterized by severe abdominal pain with or without GI disturbances, motor neuropathy, SIADH (syndrome of inappropriate antidiuretic hormone secretion), seizure, coma, encephalopathy, or psychiatric symptoms *(1)*. If not treated, acute attacks can result in paralysis or death, which is most often attributed to complications from respiratory paralysis or cardiac arrest *(2)*. Acute crises are most commonly precipitated by hormonal changes such as increases in progesterone during the luteal phase of the natural menstrual cycle, stress, severe illness, surgery, smoking, alcohol, or exposure to drugs that induce synthesis of heme or cytochrome P450 enzymes (CYP) or through other mechanisms. These stimuli upregulate 5'-aminolevulinic acid synthase 1 (*ALAS1*) expression but downstream enzymatic blocks result in pathogenic accumulation of 5-aminolevulinic acid (ALA), a water-soluble heme intermediate that shares structural similarity with γ-aminobutyric acid (GABA) and PBG. There are many potential mechanisms for the neurotoxicity observed in acute porphyric attacks, but one leading hypothesis is that ALA interferes with GABA signaling *(3)*.

[1] Department of Pathology and Laboratory Medicine, Dartmouth-Hitchcock Medical Center, Lebanon, NH; [2] The Geisel School of Medicine at Dartmouth, Hanover, NH.
* Address correspondence to this author at: Department of Pathology and Laboratory Medicine, Dartmouth-Hitchcock Medical Center, Lebanon, NH 03756. Fax 603-650-7214; e-mail Robert.D.Nerenz@hitchcock.org.
Received April 25, 2018; accepted September 4, 2018.
DOI: 10.1373/clinchem.2018.291344
© 2018 American Association for Clinical Chemistry
[3] Nonstandard abbreviations: PBG, porphobilinogen; VP, variegate porphyria; HCP, hereditary coproporphyria; AIP, acute intermittent porphyria; ADP, delta-aminolevulinic acid dehydratase deficient porphyria; CYP, cytochrome P450 enzyme; ALA, 5-aminolevulinic acid; GABA, γ-aminobutyric acid; PCT, porphyria cutanea tarda; XLP, X-linked protoporphyria; CEP, congenital erythropoietic porphyria; EPP, erythropoietic protoporphyria; HMB, hydroxymethylbilane.

Table 1. Plasma porphyrin fractionation, urine PBG, and urine porphyrin fractionation results.

	Analyte	Value
Plasma	Total porphyrins	2.5 (≤1.0 μg/dL)
	Uroporphyrin	<0.1 (≤1.0 μg/dL)
	Heptacarboxyl porphyrins	<0.1 (≤1.0 μg/dL)
	Hexacarboxyl porphyrins	<0.1 (≤1.0 μg/dL)
	Pentacarboxyl porphyrins	0.1 (≤1.0 μg/dL)
	Coproporphyrin	0.2 (≤1.0 μg/dL)
	Protoporphyrin	2.1 (≤1.0 μg/dL)
Urine	Porphobilinogen	16.2 (≤1.3 μmol/L)
	Uroporphyrin	74 (≤30 nmol/L)
	Heptacarboxyl porphyrins	18 (≤7 nmol/L
	Hexacarboxyl porphyrins	5 (≤2 nmol/L)
	Pentacarboxyl porphyrins	33 (≤5 nmol/L)
	Coproporphyrin	424 (≤110 nmol/L)

CUTANEOUS PORPHYRIAS

The cutaneous porphyrias include VP, HCP, porphyria cutanea tarda (PCT), X-linked protoporphyria (XLP), congenital erythropoietic porphyria (CEP), and erythropoietic protoporphyria (EPP). These can be further subdivided into 2 groups: those with chronic, blistering photosensitivity (PCT, VP, HCP, CEP) characterized by friable, easily damaged skin, often with blisters or erosions on sun-exposed areas, and those with acute, nonblistering photosensitivity (EPP, XLP) characterized by a burning or prickling sensation with redness and swelling shortly after sun exposure. Importantly, blistering and scarring is generally not observed in EPP and XLP. Cutaneous symptoms arise from defects in the enzymatic pathway subsequent to the assembly of hydroxymethylbilane (HMB) and with each successive step in heme synthesis, porphyrinogens become progressively less water-soluble and accumulate in skin and other solid tissues. These porphyrinogens autoxidize to photoreactive porphyins upon leaving the intracellular environment, leading to the production of reactive oxygen species that then damage the surrounding tissue. Notably, increased PBG production and neurovisceral attacks are observed in VP and HCP but not in the remaining cutaneous porphyrias *(4)*. Occasionally, ALA will be modestly increased in PCT. It is important to note that VP patients are frequently misdiagnosed with PCT because of its greater prevalence and identical skin manifestations.

VP PREVALENCE AND DISEASE TRIGGERS

Patients with VP are heterozygous for a pathogenic variant in the protoporphyrinogen oxidase (*PPOX*) gene, which encodes protoporphyrinogen oxidase. Defects in PPOX activity result in the accumulation of protoporphyrinogen IX and coproporphyrinogen III, which can be autoxidized to the photoreactive intermediates (protoporphyrin and coproporphyrin) that cause cutaneous symptoms following sun exposure. Furthermore, both protoporphyrinogen IX and coproporphyrinogen III inhibit the activity of hydroxymethylbilane synthase, resulting in accumulation of ALA and PBG *(5)*. VP is inherited with equal frequency in women and men, but symptoms are observed more frequently in women. Furthermore, the severity of presenting symptoms is quite variable because of incomplete penetrance *(6)*. The majority of patients who inherit a pathogenic mutation remain asymptomatic and affected patients may experience cutaneous symptoms, neurovisceral symptoms, or both. Because of the variable presentation and relatively low disease prevalence, VP is often misidentified as another more common condition, in many cases leading to delayed diagnosis. In some tragic cases, patients may receive drugs that further exacerbate symptoms.

WORKUP OF SUSPECTED ACUTE PORPHYRIA

The laboratory workup of an acute porphyria should begin with the measurement of urinary PBG concentration during an acute crisis. Urinary PBG demonstrates excellent sensitivity and specificity because concentrations are almost always increased in acute attacks in patients with AIP, VP, or HCP but not in patients with any other pathologic condition. Measurement of urinary ALA is less sensitive and specific because increased concentrations may also be observed in other conditions such as lead poisoning and hereditary tyrosinemia. It should be noted that it is now widely recommended that urine results should be expressed per gram or millimole creatinine. In AIP, HCP, and VP, both urinary PBG and ALA concentrations are increased, whereas in other conditions associated with increased urinary ALA concentrations, PBG concentrations are within the reference interval. Owing to low demand, a commercial kit for rapid, point-of-care PBG testing is no longer available, and treatment decisions must often be made before results are returned from the reference laboratory. As an alternative, a laboratory-developed qualitative PBG test such as the Watson–Schwartz reaction reduces turnaround time and facilitates rapid diagnosis.

Further biochemical testing is generally not an urgent matter but is necessary to differentiate between the acute porphyrias and to select a candidate for single-gene sequencing. Identification of VP is readily achieved by performing plasma fluorescence emission spectroscopy and observing an emission peak at 626 nm *(7)*. This peak is either absent or shifted to 620 nm in AIP or HCP. However, the 620-nm peak may also

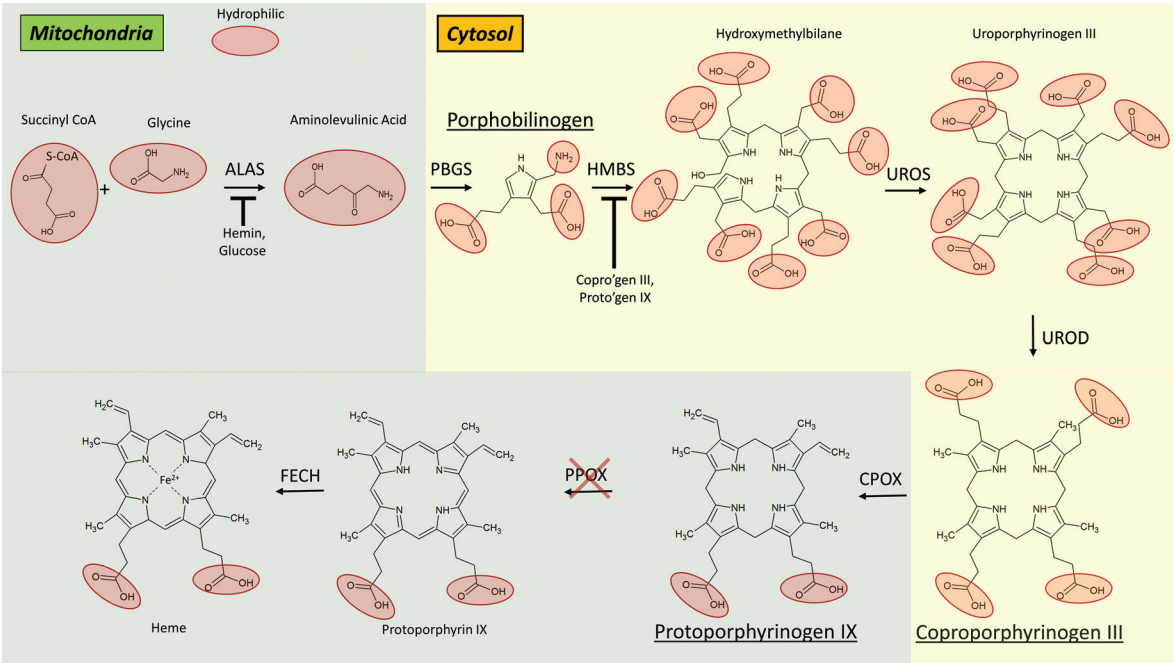

Fig. 1. Heme synthesis pathway with special emphasis on intermediates suggestive of VP.

A PPOX deficiency results in the accumulation of coproporphyrinogen III and protoporphyrinogen IX, which inhibit HMBS, resulting in accumulation of PBG. Upon leaving the intracellular environment, coproporphyrinogen and protoporphyrinogen are spontaneously oxidized to coproporphyrin and protoporphyrin, photoreactive compounds responsible for cutaneous symptoms. Hemin arginate and glucose repress *ALAS1* transcription and are indicated for the treatment of acute attacks. Porphyrin fractionation and PBG measurement performed on the patient's urine demonstrated increased concentrations of PBG and porphyrins, whereas plasma fractionation showed increased concentrations of protoporphyrin. It should be noted that not all reference laboratories include PBG measurement with urine porphyrin measurement and more often than not, this test needs to be ordered separately. Abbreviations: *ALAS,* 5-aminolevulinate synthase 1; PBGS, porphobilinogen synthase, also called delta-aminolevulinate dehydratase (ALAD); HMBS, hydroxymethylbilane synthase, also called porphobilinogen deaminase (PBGD); UROS, uroporphyrinogen III synthase; UROD, uroporphyrinogen decarboxylase; CPOX, coproporphyrinogen oxidase; PPOX, protoporphyrinogen oxidase; FECH, ferrochelatase.

be observed in VP during an acute attack, when additional types of porphyrins accumulate in plasma, making plasma fluorescence scanning less useful in this setting. If plasma fluorescence scanning is unavailable or does not show a peak at 626 nm, total fecal porphyrin measurement and fecal porphyrin fractionation should be performed. The total fecal porphyrin concentration is expected to be substantially increased in active VP and HCP, whereas it is most often normal or modestly increased in AIP. In the context of an increased total fecal porphyrin concentration, an increase in coproporphyrin III and coproporphyrin III/coproporphyrin I ratio with little increase in protoporphyrin IX is consistent with HCP, whereas in VP, both protoporphyrin IX and coproporphyrin III are substantially increased.

After initial biochemical testing has identified the likely enzymatic defect, single-gene sequencing should be performed to confirm the diagnosis and characterize the genetic variant. Targeted genetic testing of the identified variant should be offered to family members of the affected proband. Familial mutation testing should be performed on likely carriers to enable genetic counseling and avoid future diagnostic delays if symptoms occur.

ACUTE PORPHYRIA TREATMENT

Hemin is available for intravenous infusion as lyophilized hematin (Panhematin, Recordati) or as heme arginate (Normosang, Orphan Europe). Hemin treatment downregulates hepatic *ALAS1* expression and reduces the pathogenic accumulation of ALA and

PBG. Current guidelines recommend initiating hemin/heme arginate administration following detection of an increased urine PBG concentration, but initiation of treatment in the absence of a documented increase in urine PBG concentration may be justified if the clinical suspicion of acute porphyria is high. Carbohydrate loading, which also downregulates hepatic *ALAS1* but is less potent than hemin, can be used for mild attacks (those without pain requiring opioids, vomiting, paresis, seizures, or hyponatremia), or when hemin is not immediately available. Care includes managing fluids and electrolytes, providing effective analgesia, and removing crisis-inducing factors whenever possible. Gonadotropin-releasing hormone analogs may be effective for preventing frequent cyclic attacks, prophylactic hemin infusions to prevent frequent noncyclic attacks, and liver transplantation when other therapies are ineffective *(8)*.

ACUTE PORPHYRIAS AND PREGNANCY

Most women with acute porphyria do not experience attacks during pregnancy, although risks are increased for spontaneous abortion, perinatal death, low birth weight, and early delivery *(9)*. Attacks and other adverse events during pregnancy are sometimes related to delayed diagnosis and use of contraindicated medications. Treatment of attacks with hemin appears to be safe during pregnancy.

POINTS TO REMEMBER

- The acute porphyrias AIP, VP, and HCP are inherited in an autosomal dominant manner but symptom severity is variable owing to incomplete penetrance.
- Most patients with a pathogenic *PPOX* variant never experience symptoms, whereas others may experience severe cutaneous symptoms and acute neurovisceral crises.
- Measurement of urine PBG concentration should be performed during initial screening because it is almost always increased during acute crises.
- Acute crises are most often precipitated by hormonal changes, such as those observed in the luteal phase of the menstrual cycle, or exposure to CYP- or *ALAS1*-inducing drugs.
- Intravenous hemin/heme arginate suppresses the heme synthetic pathway and is front-line therapy for treatment of acute crises in both pregnant and nonpregnant patients.

CASE FOLLOW-UP

This patient carried a misdiagnosis of eczema, but cutaneous porphyria was suspected following identification of papules and scarring on sun-exposed areas and increased urine PBG concentration. Although fecal testing was not performed, increased concentrations of plasma protoporphyrin and the patient's chronic skin manifestations suggested VP, which was confirmed by the detection of a heterozygous pathogenic *PPOX* variant, c.2T>C, which is predicted to abolish the translation initiation codon and has been previously described in VP patients *(10)*.

Author Contributions: *All authors confirmed they have contributed to the intellectual content of this paper and have met the following 4 requirements: (a) significant contributions to the conception and design, acquisition of data, or analysis and interpretation of data; (b) drafting or revising the article for intellectual content; (c) final approval of the published article; and (d) agreement to be accountable for all aspects of the article thus ensuring that questions related to the accuracy or integrity of any part of the article are appropriately investigated and resolved.*

Authors' Disclosures or Potential Conflicts of Interest: *No authors declared any potential conflicts of interest.*

References

1. Pischik E, Kauppinen R. Neurological manifestations of acute intermittent porphyria. Cell Mol Biol 2009;55:72–83.
2. Pischik E, Kauppinen R. An update of clinical management of acute intermittent porphyria. Appl Clin Genet 2015;8:201–14.
3. Meyer UA, Schurrmans MM, Lindberg RL. Acute porphyrias: pathogenesis of neurological manifestations. Semin Liver Dis 1998;18:43–52.
4. Balwani M, Desnick RJ. The porphyrias: advances in diagnosis and treatment. Blood 2012;120:4496–504.
5. Meissner P, Adams P, Kirsch R. Allosteric inhibition of human lymphoblast and purified PBG-deaminase by protoporphyrinogen and coproporphyrinogen. J Clin Invest 1991;91:1436–44.
6. Whatley SD, Puy H, Morgan RR, Robreau AM, Roberts AG, Nordmann Y, et al. Variegate porphyria in Western Europe: identification of PPOX gene mutations in 104 families, extent of allelic heterogeneity, and absence of correlation between phenotype and type of mutation. Am J Hum Genet 1999;65:984–94.
7. Hift RJ, Davidson BP, van der Hooft C, Meissner DM, Meissner PN. Plasma fluorescence scanning and fecal porphyrin analysis for the diagnosis of variegate porphyria: precise determination of sensitivity and specificity with detection of protoporphyrinogen oxidase mutations as a reference standard. Clin Chem 2004;50:915–23.
8. Stein P, Badminton M, Barth J, Rees D, Stewart MF. Best practice guidelines on clinical management of acute attacks of porphyria and their complications. Ann Clin Biochem 2013;50:217–23.
9. Tollånes MC, Aarsand AK, Sandberg S. Excess risk of adverse pregnancy outcomes in women with porphyria: a population-based cohort study. J Inherit Metab Dis 2011;34:217–23.
10. Frank J, McGrath JA, Poh-Fitzpatrick MB, Hawk JL, Christiano AM. Mutations in the translation initiation codon of the protoporphyrinogen oxidase gene underlie variegate porphyria. Clin Exp Dermatol 1999;24:296–301.